

# Femtosecond Cataract

## Dr. Slade and the Femtosecond Procedure




Stephen G. Slade, MD  
Houston, Texas

*Dr. Slade has used this technique in his practice in Houston since February 2010. Patients who have traumatic cataracts, dislocated lenses or zonular dehiscence would very likely benefit from femtosecond laser cataract surgery.*

*Dr. Slade's results show a reduction in endothelial cell loss compared to manual phacoemulsification, key for cases like Fuch's Dystrophy. In addition, Dr. Slade believes that cases involving pseudoexfoliation, thickened or scarred capsules, and white cataracts would profit from the precision and flexibility of femtosecond laser cataract surgery.*

### AE-1033 Murdoch-Slade LASIK Speculum



Self-locking speculum idea for femtosecond procedures. Designed to provide maximum exposure with femtosecond lasers.

Speculum curvature accomodates the laser's docking station.

### AE-2326 Slade Femtosecond Spatula

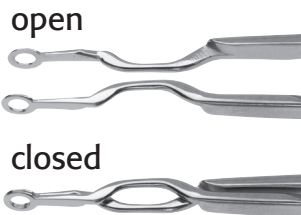
Designed with a flat tip.



Used to open the main and sideport incisions made by the Femtosecond laser. Tip is ideal for removing strands at the incision site.



### AE-4289 Akahoshi Universal Nucleus Splitter



Helps to complete the splitting of incompletely prechopped nuclei.



### AE-7654 Slade Femtosecond Cannula



Creates a more efficient hydrodissection for the Femtosecond laser procedure.

Helps to release the gas bubbles trapped beneath the nucleus during Femtosecond laser emulsification.

