

See discussions, stats, and author profiles for this publication at: <https://www.researchgate.net/publication/11445615>

Collagen Corneal Shields

ARTICLE *in* SURVEY OF OPHTHALMOLOGY · JANUARY 2003

Impact Factor: 3.85 · DOI: 10.1016/S0039-6257(01)00304-6 · Source: PubMed

CITATIONS

45

READS

69

3 AUTHORS, INCLUDING:



[Colin E Willoughby](#)

University of Liverpool

74 PUBLICATIONS 1,491 CITATIONS

[SEE PROFILE](#)

THERAPEUTIC REVIEWS

JOEL MINDEL, EDITOR

Collagen Corneal Shields

C. E. Willoughby, FRCOphth,^{1,2} M. Batterbury, FRCOphth,^{1,2}
and S. B. Kaye, MD, FRCOphth¹

¹*St Paul's Eye Unit, Royal Liverpool University Hospital, Liverpool, United Kingdom, and* ²*Unit of Ophthalmology, Department of Medicine, University of Liverpool, Liverpool, United Kingdom*

Abstract. Collagen corneal shields were developed as a corneal bandage lens and are currently indicated for ocular surface protection following surgery and in traumatic and nontraumatic corneal conditions. Collagen shields are manufactured from porcine or bovine collagen and three different collagen shields are currently available with dissolution times of 12, 24, and 72 hours. The theoretical, experimental, and clinical evidence supports a role for collagen corneal shields as a drug delivery device and in the promotion of epithelial and stromal healing. Presoaking the collagen shield in a pharmacological agent with adjunctive topical treatment represents the most efficacious method of utilizing collagen shields for drug delivery. In microbial keratitis collagen shields can enhance drug delivery, promote epithelial and stromal healing, neutralize collagenases, and reduce corneal inflammation. This review will examine the evidence that supports the role of collagen shields in drug delivery and corneal wound healing. Despite a large volume of experimental (animal) work, studies on human subjects, particularly randomized controlled trials, are lacking. The authors are advocating the reassessment of the application and benefits of corneal collagen shields to clinical practice. (*Surv Ophthalmol* 47:174–182, 2002. © 2002 by Elsevier Science Inc. All rights reserved.)

Key words. collagen shield • cornea • corneal healing • drug delivery • microbial keratitis

Collagen corneal shields were developed by Fyodorov in 1984²⁰ as a corneal bandage lens following radial keratotomy and photorefractive surgery. Initially, rigid PMMA (polymethyl-methacrylate) scleral contact lenses⁵⁴ and subsequently hydrogel bandage contact lenses were used as such in a variety of clinical situations.²¹ Collagen was introduced as a wound-healing agent in the management of burns and skin ulceration in the 1970s,^{13,64} and the biocompatibility and biodegradability of collagen, along with its ability to support corneal epithelial cells in culture,²⁵ led to the development of collagen corneal shields as an ocular surface bandage. Studies using animal and

human subjects have investigated collagen shields as a drug delivery device and in the promotion of corneal epithelial and stromal healing.^{19,40}

Collagen shields have been commercially available for over 10 years, yet they are not widely utilized. Collagen shields are currently labeled for ocular surface protection following surgery and in traumatic and nontraumatic corneal conditions. Caution is recommended by manufacturers when collagen shields are used on patients with infected or diseased corneas. Despite a large volume of experimental (animal) work, studies on human subjects, particularly randomized controlled trials, are lacking. The

authors are advocating the reassessment of corneal collagen shields in clinical practice.

This review addresses those considerations that need to be assessed before advocating a wider application for corneal collagen shields, such as efficacy, side effects, and cost. Visual acuity is reduced to 6/36–6/60 while the shield is in place,^{55,67} and this may represent a significant consideration, especially if the contralateral eye is visually compromised. The cost of a corneal collagen shield is approximately US\$ 30 to 40, and this must be evaluated against the savings from shorter hospitalization and reduced nursing requirements. The authors will also describe their own experience.

Specifications

Collagen shields are currently manufactured from porcine scleral tissue or bovine corium (dermis) collagen and contain mainly type I collagen and some type III collagen. They are shaped like a contact lens and are supplied in a dehydrated form, requiring rehydration prior to insertion. Variations in collagen crosslinking induced with ultraviolet light (UV) during manufacture dictate lens duration before dissolution. Three different collagen shields are currently available with dissolution times of 12, 24, and 72 hours. Corneal collagen shields have a diameter of 14.5–16.0 mm, a base curve of 9 mm, and a central thickness of 0.15–0.19 mm.⁴⁰ A detailed study of the oxygen transmissibility of Bio-Cor (Bausch and Lomb, Clearwater, FL) collagen shields⁷⁰ in vitro indicated that they behave like a 63% water-content hydrogel contact lens with an average oxygen permeability (Dk/L) of $27 \times 10^{-11} \text{ cm}^2 \text{ mL O}_2/\text{s mL mm Hg}$. The Dk value is the volume of oxygen in ml passing in 1 second through a contact lens material 1 cm thick and area 1 cm² for every 1-mm Hg partial pressure difference across the material at 35°C. The Dk/L value is usually given in which L equals central sample thickness. This Dk/L value is equivalent to an open-eye HEMA (hydroxyethyl-methacrylate) contact lens but would be considered borderline for use as an extended wear closed-lid lens.²⁹ As dissolution occurs, however, central thickness decreases and hydration increases so that in vivo the Dk/L values increase exponentially with degradation.³ In human subjects, mean corneal thickness measured by ultrasound pachymetry increased by 4% with a 70% water content hydrogel contact lens and 3% with a collagen shield after 24 hours of wear, suggesting that corneal stress was equivalent for both devices.⁵⁵

Drug Delivery

The natural biodegradability and absorptive capacity of collagen⁴ have led to the development of collagen shields as drug delivery devices in a variety

of situations.¹⁹ Antibacterials, antifungals, antivirals, anti-inflammatory, immunosuppressive, and anticoagulant agents have been delivered with collagen shields.¹⁹ The pharmacokinetics of collagen shield drug delivery has been studied in vitro and in vivo, mainly utilizing animal models. Collagen shields can act as a pre-corneal drug reservoir, producing a prolonged contact time, higher contact concentrations, and increased drug bio-availability.^{19,40}

Drug delivery depends on absorption and subsequent release of medication by the collagen shield. Water-soluble drugs are trapped within the collagen matrix and some drugs (e.g., vancomycin) undergo reversible binding to collagen.⁴⁷ Water-insoluble drugs (e.g., cyclosporin A) must be incorporated into the shield when manufactured.^{11,51} The collagen shield rapidly becomes saturated when placed in a water-soluble drug solution; greater drug absorption occurs when the shield is soaked with high drug concentrations.⁶⁵ Experimental in vitro studies suggest drug exposure times of 5–10 minutes are adequate to achieve maximal drug absorption.^{32,47} Plateau levels of drug absorption occur after a 5–10-minute soak in ofloxacin (3 mg/ml) in vitro with use of either a 24-hour or 72-hour collagen shield.³² A 5–10-minute soak in tobramycin (40 mg/ml or 200 mg/ml)⁶⁵ or gentamicin (40 mg/ml)⁴⁷ with use of a 72-hour collagen shield gave an equivalent drug absorption as a 2-hour soak.

The degree of UV-induced collagen crosslinking during manufacture influences shield dissolution times and the efficacy of the shield as a drug delivery device.³² Crosslinked collagen shields (dissolution time 24–72 hours) act as drug reservoirs, allowing drug concentrations to reach higher levels in the anterior segment over a sustained period of time.³² Non-crosslinked or 12-hour collagen shields are less effective as a drug delivery system due to their rapid dissolution.³² In vivo studies in rabbits with non-crosslinked (12-hour) shields³² containing gentamicin,⁴⁷ found that the shield had disappeared within 1 hour,³² releasing the gentamicin in a pulse effect over 30 minutes.⁴⁷ The rapid dissolution of the 12-hour shield was attributed to proteolytic degradation from enzymes in the tears, and it was proposed that the amounts of collagen crosslinking were inversely related to the rates of proteolytic enzymatic degradation.³² The absence of tear enzymes may explain why vancomycin was released from a 12-hour shield for a longer period, 6 hours, when studied in vitro.⁴⁸

A variety of investigations have demonstrated that corneal collagen shields are comparable or superior to topical drops, subconjunctival injections, and hydrogel contact lenses for drug delivery.^{8,12,14,19,28,31,32,38,40,45,47,57,58,65} Presoaking the collagen shield in a

pharmacological agent with adjunctive topical treatment represents the most efficacious method of utilizing collagen shields for drug delivery.^{8,12,14,28,31,38,45,}

⁵⁷ Comparisons of drug delivery between studies can be difficult due to non-standardized experimental conditions. The majority of these studies utilize rabbit models and are not directly comparable to human subjects due to differences in tear volume, blink rate, and corneal thickness. Despite these problems, the experimental evidence suggests that collagen shield drug delivery is equivalent or superior to conventional delivery vehicles.

COLLAGEN SHIELD VERSUS TOPICAL DRUG DELIVERY

Collagen shields have been compared with topical treatment primarily for antimicrobial (mainly aminoglycoside) and corticosteroid drug delivery. Rabbit gentamicin and vancomycin corneal and aqueous drug levels were equivalent or superior at 2 to 6 hours with use of a presoaked 12-hour collagen shield without topical supplementation, compared to intensive topical treatment.⁴⁷ Placing topical tobramycin drops on an unsoaked collagen shield, when compared to topical treatment alone, produced a 30-fold increase in aqueous levels at three hours in a rabbit model.⁵⁷ A 12-hour collagen shield presoaked in tobramycin with supplemental topical treatment produced significantly higher aqueous levels ($p < 0.05$) than topical treatment alone at 15 and 60 minutes in a rabbit model.⁴⁵ The experimental evidence suggests that a presoaked collagen shield with less intensive supplemental topical therapy is an acceptable alternative to intensive topical treatment.^{8,12,14,28,45} The enhanced drug delivery by collagen shield is reflected in studies of experimental rabbit Staphylococcal and *Pseudomonas* keratitis that demonstrate enhanced bacterial eradication.^{8,14,28,57}

Collagen shields also enhance prednisolone acetate delivery.⁵⁸ A 12-hour collagen shield presoaked in prednisolone for 15 minutes, when compared to a single topical application in a rabbit model,⁵⁸ delivered a 4- to 5-fold increase in corneal/aqueous levels at 30 minutes and a 100- to 200-fold increase at 120 minutes. Collagen shield delivery of dexamethasone alcohol has been compared to a variety of eye drop dosing regimes in a rabbit model, and superior peak and cumulative doses of dexamethasone are obtained with the collagen shield.³¹ Dexamethasone was released gradually over a 10-hour period in vitro.³⁸ A 24-hour collagen shield presoaked for 20 minutes in 0.1% dexamethasone produced a 2- to 5-fold increase in tissue levels, compared to a single drop, and was equivalent or superior to hourly topical treatment. In addition, when the presoaked shield was supplemented with hourly topical ther-

apy, a further 2- to 3-fold increase in tissue levels was achieved.³¹

COLLAGEN SHIELD VERSUS SUBCONJUNCTIVAL INJECTION DRUG DELIVERY

Collagen shields (72-hour) soaked in tobramycin (40 mg/ml and 200 mg/ml) gave equivalent and significantly higher corneal and aqueous humor concentrations at 1 hour than a 20-mg subconjunctival injection in a rabbit model. The levels obtained at 8 hours were above the mean inhibitory concentration (MIC) for *Pseudomonas* (0.25–4.00 µg/ml).⁶⁵ Collagen shields presoaked in gentamicin and dexamethasone without topical supplementation produced comparable drug levels in the aqueous humor over a 10-hour test period.³⁸ Subconjunctival drug delivery, unlike collagen shields, has the potential to produce non-uniform corneal drug levels,⁴⁴ tissue necrosis, and sight-threatening complications due to inadvertent ocular perforation and macular infarction.¹⁰

COLLAGEN SHIELD VERSUS HYDROGEL CONTACT LENS DRUG DELIVERY

Soft hydrogel lenses have been utilized as a sustained-release drug delivery system but a pulse effect of drug release is probably the major means of drug delivery, with total drug release occurring within 4 hours.^{27,30,38,47} The pharmacokinetics of drug delivery by different types of soft contact lenses are non-reproducible because of variations in the drug concentration gradients, and the structure, polymer material, and water content of the contact lens.^{30,35,36,50} In a mathematical model of the pharmacokinetics of drug delivery with bandage contact lenses,³⁶ the main pathway of drug delivery was around the edge of the contact lens with the tear film posterior to the lens acting as a drug depot. Accordingly, drug delivery would be influenced by tear production and contact lens fit, with a parallel fit lens delivering optimum drug levels.³⁶ In an eye with epiphoria, topical medication had to be applied to an unsoaked contact lens every 5 minutes to maintain significant drug levels in the tear film posterior to the lens, compared with every 30 minutes in an eye without epiphoria. Topical drug instillation at intervals less frequent than every 30 minutes was inadequate to allow significant drug accumulation in the tear film under the contact lens.³⁶

Few studies have directly compared drug delivery by hydrogel lenses with collagen shields. In one study, presoaked collagen shields gave a significantly greater penetration of tobramycin into the aqueous humor than hydrophilic contact lenses or topical therapy.⁴⁵ Two separate studies used similar methods, but their drugs had markedly different lipid solubility—prednisolone acetate being much more

lipid-soluble than prednisolone sodium phosphate. Presoaked hydrophilic contact lenses enhanced the ocular penetration of prednisolone sodium phosphate 2- to 3-fold in the cornea (35.1 $\mu\text{g}/\text{ml}$ at 120 minutes) and aqueous (3.8 $\mu\text{g}/\text{ml}$ at 120 minutes),³⁰ compared to topical administration. Collagen shields presoaked in prednisolone acetate increased drug levels 100- to 200-fold in the cornea (214 $\mu\text{g}/\text{ml}$ at 120 minutes) and aqueous (32.9 $\mu\text{g}/\text{ml}$ at 120 minutes),⁵⁸ compared to topical administration. Interestingly, the application of prednisolone sodium phosphate with an unsoaked hydrophilic lens in situ produced lower anterior segment levels at 1 and 2 hours than without a contact lens in place. The explanation seemed to be that 11–14% of the prednisolone was bound to the lens and so unavailable for release.³⁰

Collagen shields thus appear to give equivalent or superior drug delivery when compared to hydrogel contact lenses, and they have other advantages. There are fewer fitting difficulties with collagen shields, and, with collagen dissolution, there is superior oxygen transmission.¹¹ It has been extensively demonstrated that soft contact lenses can bind microorganisms, including *Pseudomonas*.^{7,15} There has been only one report of adherence of *Pseudomonas* to a collagen shield.⁵ No evidence of bacterial adherence on collagen shields, however, was found using scanning electron microscopy in two patients with bacterial keratitis.⁵⁹ The continuous dissolution of the collagen shield may prevent bacterial adherence.^{45,57} No infection was reported in eight separate studies involving a cumulative total of 292 post-surgical patients (cataract extraction, penetrating keratoplasty, epikeratophakia),^{3,34,49,52,56} and 38 patients with ocular surface disease.^{26,40,67} One concern that has been raised is that the dissolving collagen might act as a nutrient for pathogenic organisms. There is no experimental evidence that the collagen constituting the corneal shield can support bacterial growth. Animal studies evaluating *Pseudomonas* keratitis not treated with antibiotics found there were no differences in the number of colony-forming units between eyes receiving collagen shields soaked in saline and those that did not. That is, there was no evidence of collagen shields enhancing bacterial growth. Existing evidence, to be discussed subsequently, demonstrates that when corneal collagen shields are presoaked in antibiotics and receive supplemental topical therapy every 4–6 hours, they are optimally being employed in microbial keratitis.

Collagen corneal shields, similar to bandage contact lenses, are well tolerated with regard to comfort,^{3,26,34,49,52,55,56,67} but the former reduce the vision to 6/36–6/60.^{55,67} This may represent a significant consid-

eration, especially if the contralateral eye is visually compromised. In clinical situations with sight-threatening ocular conditions, such as *Pseudomonas* keratitis, reduction in visual acuity would most likely already be caused by the ocular pathology. In other less-threatening applications, the reduction in visual acuity produced by the collagen shield might be deemed a significant factor that limits its use.

Corneal Epithelial and Stromal Healing

Collagen was initially used in third-degree skin burns to enhance epithelial healing by preventing desiccation, providing a mechanical and bacterial defense, and reducing discomfort.^{13,64} Corneal collagen shields may have a similar role in corneal wound healing. Animal models with corneal epithelial defects and superficial keratectomy and radial keratotomy wounds have demonstrated that collagen shields can enhance re-epithelialization and reduce stromal inflammation and edema.^{1,18,61,63}

Corneal healing studies in human subjects following radial keratotomy, cataract surgery, epikeratoplasty, and penetrating keratoplasty support a role for collagen shields in promoting re-epithelialization.^{2,49,56} For acute epithelial defects, collagen shields represent a good alternative to conventional methods to promote re-epithelialization.^{49,67} However, 24-hour collagen shields appear less effective in healing chronic corneal ulcerations.^{26,49} In the treatment of persistent epithelial defects after penetrating keratoplasty, a bandage contact lens was more effective than 24-hour collagen shields.²⁶ The 24-hour collagen shields were continuously replaced as they dissolved. The need for frequent replacement of collagen shields is believed to be the reason they are less efficacious in chronic situations.⁴⁹ The authors suggest that the use of a longer lasting collagen shield (72-hour) might be more effective.²⁶

The positive results of early clinical studies^{2,49} stimulated experimental work on the influence of collagen shields on corneal epithelial healing kinetics. These quantitative studies in animal models have utilized a variety of experimental methods and differ in the nature of wound creation, for example, chemical versus mechanical debridement. They also vary in the type of animal model used, whether nictitating membranectomy was performed, the type of collagen shield employed, the use of prophylactic antibiotics, and the initial wound size. For example, following superficial keratectomies (0.1-mm depth) in rabbits¹⁸ and mechanical debridement in cats, collagen shields enhanced re-epithelialization,⁶¹ whereas following a deeper keratectomy (0.2-mm depth)⁹ or chemical debridement⁵⁴ in rabbits, they had no significant effect on re-epithelialization. In spite of these variations, the majority of studies have reported an en-

hanced epithelial healing response with collagen shields. A comparison of collagen shields to therapeutic contact lenses in a rabbit model following mechanical debridement demonstrated that both modalities significantly accelerated epithelial healing.⁶³ One presumed mechanism is the protection of migrating regenerating epithelial cells from the mechanical effects of the eyelids, ensuring epithelial proliferation and adherence.^{2,18,40,61,63}

Destruction or removal of the rabbit corneal epithelium is associated with keratocyte loss in the anterior stroma^{16,43} and may be related to the development of subepithelial haze and variable refractive outcomes following human photorefractive keratectomy (PRK).¹⁶ Collagen shields, especially when soaked in a solution containing 1% dextran, 2.5% chondroitin sulfate, vitamins, and precursors of adenosine triphosphate,⁴³ prevented keratocyte loss in rabbits following mechanical epithelial debridement.⁴³ Collagen shields thus might have a role following PRK not only in enhancing re-epithelialization, but in reducing any possible keratocyte loss and potentially reducing subepithelial haze.

Polymorphonuclear (PMN) leucocytes can inhibit corneal epithelial wound healing *in vitro*⁶⁷ and generate collagenases, producing corneal stromal lysis. Following radial keratotomy and superficial keratectomy wounds, collagen shields reduce the inflammatory and PMN reaction, stromal edema, and keratocyte reaction, while at the same time promoting corneal epithelial healing.^{18,34} In rabbit eyes following superficial keratectomy, large numbers of PMNs were found by scanning electron microscopy entrapped within the collagen matrix of the shields.¹⁸ The collagen shields acted as a substrate for PMN adherence and colonization, with subsequent phagocytosis and enzymatic degradation of the shield's collagen matrix by the PMNs and eventual shield disintegration.^{18,22} One study in a rabbit model following bilateral keratectomy interpreted the infiltrate as eosinophils and postulated an immunologic, as well as inflammatory, reaction to the collagen shield.⁹ However, rabbit neutrophils have red-staining cytoplasmic granules on hematoxylin and eosin staining, and a Luna stain, which is specific for eosinophils, should have been employed to differentiate the rabbit eosinophils from neutrophils.³⁹ Using an antineutrophil antibody, the majority of cells in the collagen shield in human subjects were identified as neutrophils.²²

Collagenases liberated from keratocytes, epithelial cells, PMNs, and bacteria produce corneal stromal lysis and have been implicated in the pathogenesis of corneal ulceration and melting disorders.^{14,59,69} The rate of collagen shield dissolution may also be a clinical indicator of collagenase activity.^{59,69} Collagen

shields seem to have a therapeutic role in this setting by acting as a substrate for collagenases and PMN phagocytosis, thereby limiting corneal stromal collagen destruction as well as restoring the integrity of the corneal epithelium.^{59,63,69} Collagen breakdown products liberated from the shield can also be utilized by migrating corneal epithelial cells to aid the orientation of renewed stromal collagen fibrils.²³ Thus, as with epithelial healing, most, but not all, studies⁷⁰ support a role for collagen shields stromal healing.

Microbial Keratitis

The principle goals in the management of microbial keratitis are the eradication of the infectious agent, restoration of the ocular surface, and minimization of corneal scarring.¹⁴ Collagen shields can contribute to achieving these goals by enhancing drug delivery, promoting epithelial and stromal healing,^{1,2,18,49,56,61,63} neutralizing collagenases generated from leucocytes and bacteria,^{23,59,63} and reducing corneal inflammation and edema.^{18,34}

The principle treatment for microbial keratitis is the application of intensive fortified topical treatment to ensure adequate bactericidal concentration.^{14,24} High initial drug levels are desirable and loading doses every minute for 5 minutes followed by intensive topical therapy can maintain sustained corneal levels above the minimal inhibitory concentration (MIC).²⁴ Corneal drug levels with collagen shields are equivalent or superior to intensive topical treatment, therapeutic contact lenses, and subconjunctival injections, with adjunctive and less-frequent topical treatment further enhancing drug delivery.^{8,12,14,28,31,45,57} The rapid shield dissolution by collagenases produced in bacterial keratitis may titrate antimicrobial delivery with disease activity and alter drug bio-availability; hence, an intense keratitis induces rapid dissolution and so rapid drug delivery.⁵⁹ When considering combination drug therapy in microbial keratitis drug compatibility must be considered. For example, vancomycin and gentamicin have been combined and effectively delivered via a collagen shield system;⁴⁷ however, gentamicin and cefazolin precipitate and penicillins inactivate aminoglycosides.¹⁹

Drug delivery may be altered in the inflamed eye especially in the presence of an epithelial defect, which will improve corneal drug levels from topical therapy. However, even in the presence of an epithelial defect, collagen shield delivery of tobramycin significantly exceeded topical therapy.¹² Rabbit models of Staphylococcal and *Pseudomonas* keratitis demonstrated comparable^{6,28} or superior^{14,57} pharmacodynamic efficacy using collagen shields versus topical treatment. In rabbit corneas infected with *Pseudomonas*, collagen shields presoaked in tobramycin were

as effective in lowering bacterial counts as half-hourly drops over a 4-hour test period.²⁸ There was also a significant decrease in colony-forming units using an unsoaked collagen shield with half-hourly topical tobramycin, compared to topical treatment alone over a 12-hour test period.⁵⁷ Collagen shields presoaked in tobramycin (1.36%) with supplemental, fortified topical tobramycin drops (1.36%) eradicated an experimental rabbit Staphylococcal keratitis with less-frequent dosing than required for topical treatment alone.⁸ Presoaked collagen shields supplemented with topical tobramycin applied every 1, 2, or 5 hours sterilized 100% of rabbit corneas with Staphylococcal keratitis, whereas 100% sterilization could be achieved without the collagen shields only when topical tobramycin was applied hourly.⁸ Presoaked collagen shield delivery without topical supplementation of amphotericin B is comparable to topical therapy both in vitro⁶⁰ and in vivo in the treatment of *Candida albicans*-induced keratomycosis in rabbits.⁴⁸

Treating *Pseudomonas* keratitis with a 72-hour collagen shield containing tobramycin, supplemented with topical tobramycin drops every 4–6 hours, resulted in significantly fewer colony-forming units after 24 hours than hourly topical therapy alone ($p < 0.001$).¹⁴ However, a 24-hour collagen shield presoaked in gentamicin (13.6 mg/ml) supplemented with topical gentamicin every 3 hours was not as effective as half-hourly topical therapy over a 24-hour period.⁶² These conflicting findings may be due to the use of collagen shields with different dissolution times. As previously mentioned, in vivo studies in rabbits without keratitis found that non-crosslinked (12-hour) shields disappeared within 1 hour.³² Shield dissolution may be further accelerated by corneal and/or bacterial collagenases⁵⁹ generated by the experimental keratitis. A similar study with a 72-hour collagen shield, which remained for in situ for 24 hours, showed significant benefit in reducing colony-forming units.¹⁴ The experimental evidence, therefore, suggests that a presoaked collagen shield with less-intensive supplemental topical therapy is an acceptable alternative to intensive, fortified topical treatment in microbial keratitis.

Collagen shields seem to require less-intensive supplemental dosing regimes, which might offer an additional benefit, namely, less corneal epithelial toxicity. Fortified gentamicin eyedrops (10 mg/ml) slightly reduce corneal epithelial regeneration, but at a concentration of 14 mg/ml a marked reduction occurs.⁴⁶ The total dose of tobramycin supplied after soaking a collagen shield (dissolution time not stated by authors) in a 4% solution is 800 μg .²⁸ However, the peak and more persistent tobramycin levels provided by the collagen shield could be just as, or more, toxic than fortified eyedrops. Few studies have

addressed this potential for epithelial toxicity when collagen shields are used. In one rabbit model, epithelial toxicity was assessed over an 8-hour test period using 72-hour collagen shields soaked in two concentrations of preservative-free tobramycin, 40 mg/ml and 200 mg/ml.⁶⁵ There was no evidence of epithelial toxicity from the former, but there was with the latter.⁶⁵ When the experiment was repeated with tobramycin, 40 mg/ml, with various preservatives (benzalkonium chloride 0.01%; phenol 0.5%; edetate sodium 0.01%), again, no evidence of epithelial toxicity was found.⁶⁵ These studies support the belief that collagen shields presoaked in tobramycin (40 mg/ml) with adjunctive topical therapy every 4–6 hours will be pharmacokinetically, pharmacodynamically, and physiologically comparable or superior to the “gold standard” of intensive fortified eyedrops on microbial keratitis.

Collagen shields can also enhance the patient's comfort during drug delivery and the number of hours of undisturbed sleep, while reducing labor-intensive nursing requirements. Collagen shields have advantages when frequent instillation is difficult, for example in the pediatric, mentally handicapped, and elderly populations, and may even avoid or reduce the duration of hospitalization. These benefits and the efficacy of collagen shields may offset the main criticisms of collagen shields, that is, their expense, costing US\$ 30 to 40 each. Clinical studies are required to prove these expectations.

Other Applications

Collagen shields have been used in a variety of clinical situations. Collagen shield delivery of dexamethasone or cyclosporin may have a role in the management of rejection following corneal transplantation.^{11,33} In a rabbit model of allograft corneal rejection, collagen shields impregnated with cyclosporin A (CsA) produced a 250% increase in mean graft survival versus topical CsA. These results were also supported by histological evidence of a reduction in the immune response.¹¹ Collagen shield CsA delivery was as effective as oral CsA in suppressing allograft rejection in an animal model of high-risk penetrating keratoplasty.³³ The enhanced delivery of immunosuppressives like cyclosporin and steroids^{31,58} with collagen shields may have a role in the treatment of other intra-ocular inflammatory disorders like uveitis, particularly in situations when frequent instillation is difficult. Collagen shields have been utilized in rabbit models to successfully deliver heparin in the prevention of fibrinous uveitis⁴² and tissue plasminogen activator (tPA) for fibrin clot lysis.⁴¹ Collagen shields have also been used to promote healing of leaking blebs after filtration surgery.¹⁷ Following lid surgery, collagen shields reduced postop-

erative injection, chemosis, and edema, and improved patient comfort,³⁷ although the mechanism of these findings are not addressed.

Practical Considerations

As mentioned previously, collagen shields are currently marketed for ocular surface protection following cataract and refractive surgery, penetrating keratoplasty, and traumatic epithelial defects. Manufacturers recommend caution when using collagen shields on patients with infected or diseased corneas.

Patients with allergies to collagen or bovine/porcine-derived products should be excluded. The physician should warn the patient about temporary stinging on insertion and the reduction in visual acuity to 6/36–6/60 while the shield is in place.^{55,67} The latter is especially important if the contralateral eye is visually compromised.

Collagen shields are normally stored at room temperature and supplied in a dehydrated form in sterile, individual packaging (Fig. 1A). The dissolution times quoted are for non-patched eyes and the shields are supplied in 12-, 24-, and 72-hour duration forms. Patching the eye extends the dissolution times. The shield is hydrated either in the sterile packaging or in a sterile receptacle with the drug of choice or balanced salt solution. Only water-soluble drugs can be used in this way, water-insoluble agents must be incorporated into the shield during manufacture. The shield is completely immersed for 3–5 minutes and handles like a high water-content bandage lens (Fig. 1B). Instill topical anaesthetic into the patient's eye and then some of the hydrating solution to moisten the cornea. Handle the lens with sterile blunt forceps (Fig. 1B) and place on the eye in downgaze, with the lids retracted by an assistant, as if applying a bandage lens. Invert the peripheral

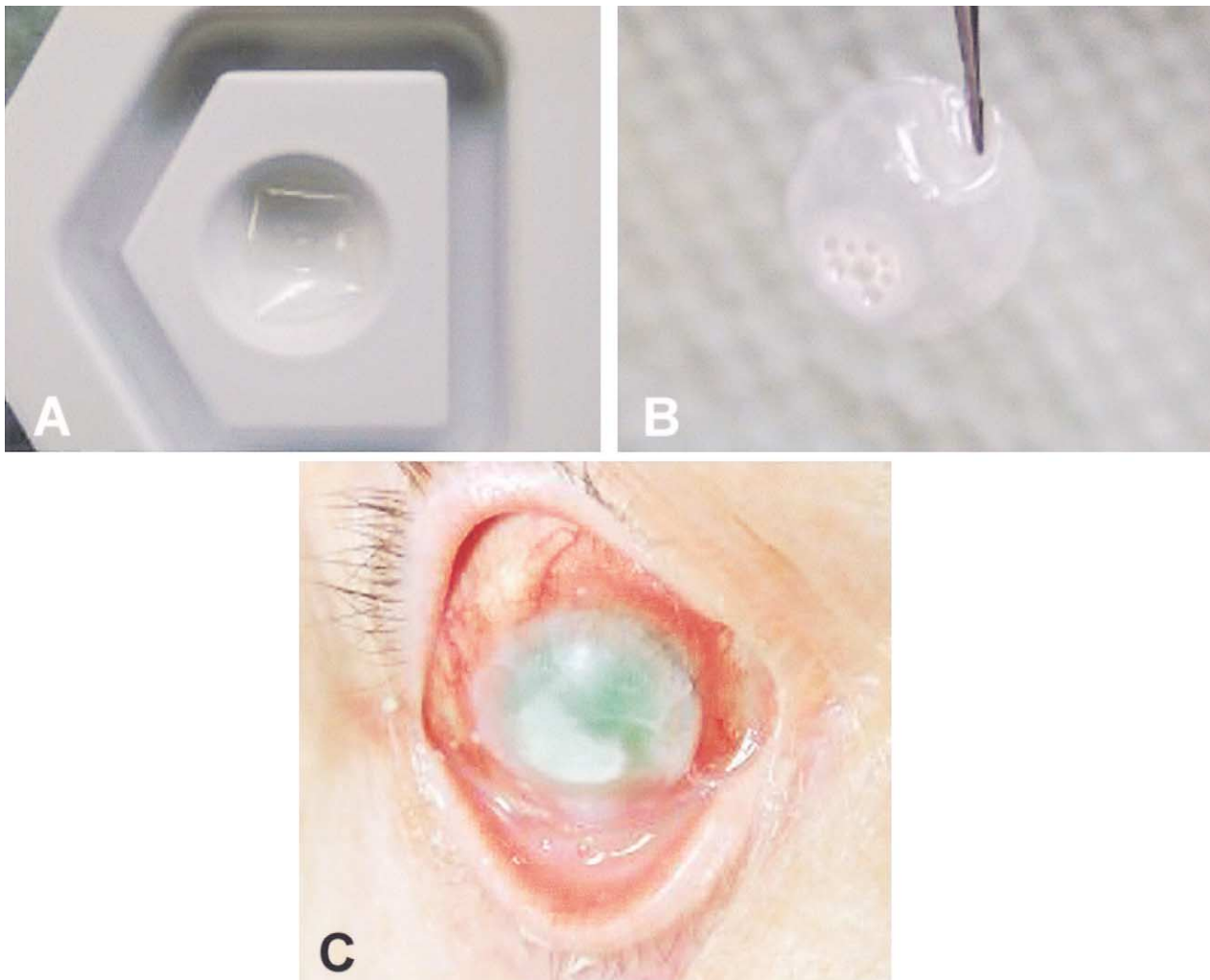


Fig. 1. A: Corneal collagen shield in sterile packaging prior to re-hydration. B: Re-hydrated corneal collagen shield (72-hour) following 5-minute soak in prednisolone acetate (1%). C: Corneal collagen shield (72-hour) presoaked in ciprofloxacin (0.3%) in a patient with bacterial keratitis.

edge of the shield with slight pressure from the forceps. Apply slight pressure through the closed eyelid for approximately one minute to allow the shield to conform to the corneal surface. Temporary stinging may occur as the collagen shield has a low pH. The surface pH of the shield can be neutralized by soaking the shield several times in fresh hydrating solution. We find, however, that topical instillation of the hydrating solution every few minutes for 15 minutes is sufficient and aids conformation of the shield to the eye.

We recommend using the 72-hour shield as a drug delivery device and/or in corneal epithelial healing. This is based on the evidence we have already discussed and practical considerations. We found the 12-hour shield difficult to handle, less stable on the ocular surface, and with a tendency to break up after 2–3 hours in microbial keratitis. The 72-hour shield is much easier to handle (Fig. 1B), and more stable on the ocular surface. We have used 72-hour collagen shields presoaked in ciprofloxacin (3 mg/ml) in bacterial keratitis (Fig. 1C), and prednisolone acetate 1% (Fig. 1B) in vernal ulceration and anterior uveitis. The patients received the presoaked shields and adjunctive topical therapies every 6 hours. The eyes were examined regularly and the shields replaced when dissolved. The shield dissolution rate increases in microbial keratitis. Patching may be required to prevent shield folding and extrusion and/or enhance patient comfort. We feel collagen shields offer the most benefit in microbial keratitis and as drug delivery devices, particularly in situations where frequent topical therapy is difficult.

Conclusions

The theoretical, experimental, and clinical evidence supports a role for collagen corneal shields as drug delivery devices, as well as in the promotion of epithelial and stromal healing. The experience of the authors is that 72-hour collagen shields are preferred for both indications. Collagen shields seem to offer a number of advantages in the treatment of microbial keratitis. These should be addressed in controlled clinical trials. The potential role of collagen shields in the management of ocular disease suggested from experimental evidence should be evaluated further in clinical studies.

Method of Literature Search

The literature search was performed using the PubMed and Medline databases. Search words included *collagen corneal shields* or *collagen shields* combined with *drug delivery*, *corneal healing*, *antibiotics*, *microbial keratitis*, *keratitis*, *corneal ulceration*, *ocular surgery*, and *contact lens*. The search covered the years 1966 to the present and non-English articles were in-

cluded if pertinent. Copies of the entire article were obtained and cited in the evidence reviewed.

References

1. Aquavella JV, del Cerro M, Musco J, et al: The effect of collagen bandage lens on corneal wound healing. A preliminary report. *Ophthalmic Surg* 18:570–3, 1987
2. Aquavella JV, Musco J, Veda S: Therapeutic applications of collagen bandage lenses: a preliminary report. *CLAO J* 14: 47–50, 1988
3. Aquavella JV, Ruffini JJ, Lo Cascio JA: Use of collagen shields as a surgical adjunct. *J Cataract Refract Surg* 14:492–5, 1988
4. Arem A: Collagen modifications. *Clin Plast Surg* 12:209, 1985
5. Asbell PA, Namdari H, Hartman EJ: Microbial adhesion and growth on collagen shields. *Invest Ophthalmol Vis Sci* 32 (Suppl): 1166, 1991
6. Assil KK, Zaenegar SR, Fouraker BD, Shanzhi DJ: Efficacy of tobramycin-soaked collagen shields vs tobramycin eyedrop loading dose for sustained treatment of experimental *Pseudomonas aeruginosa*-induced keratitis in rabbits. *Am J Ophthalmol* 113:418–23, 1992
7. Butrus SI, Klotz SA, Misra RP: The adherence of *Pseudomonas aeruginosa* to soft contact lenses. *Ophthalmology* 94:1310, 1987
8. Callegan MC, Engel LS, Clinch TE, et al: Efficacy of tobramycin drops applied to collagen shields for experimental staphylococcal keratitis. *Curr Eye-Res* 13:875–8, 1994
9. Callizo J, Cervello I, Mayayo E, Mallol J: Inefficacy of collagen shields in the rabbit corneal wound-healing process. *Cornea* 15:258–62, 1996
10. Campochario PA, Conway BP: Aminoglycoside toxicity—a survey of retina specialists. *Arch Ophthalmol* 109:946–50, 1991
11. Chen YF, Gebhardt BM, Reidy JJ, Kaufman HE: Cyclosporine-containing collagen shields suppress corneal allograft rejection. *Am J Ophthalmol* 109:132–7, 1990
12. Chen CC, Takuri H, Duzman E: Enhancement of the ocular bioavailability of topical tobramycin with use of a collagen shield. *J Cataract Refract Surg* 19:242–5, 1993
13. Chvapil M, Kroenthal R, VanWinkle W: Medical and surgical applications of collagen. *Int Rev Conn Tissue Res* 6:1, 1973
14. Clinch TE, Hobden JA, Hill JM, et al: Collagen shields containing tobramycin for sustained therapy (24 hours) of experimental *Pseudomonas* keratitis. *CLAO J* 18:245–7, 1992
15. Cohen EJ, Laibson PR, Arentsen JJ, Clemons CS: Corneal ulcers associated with cosmetic extended wear soft contact lenses. *Ophthalmology* 94:109–14, 1987
16. Del Pero RA, Gigstad JE, Roberts AD, et al: A refractive and histopathologic study of excimer laser keratectomy in primates. *Am J Ophthalmol* 109:419–29, 1990
17. Fourman S, Wiley L: Use of a collagen shield to treat a glaucoma filter bleb leak. *Am J Ophthalmol* 107:673–4, 1989
18. Frantz JM, Dupuy BM, Kaufman HE, Beuerman RW: The effect of collagen shields on epithelial wound healing in rabbits. *Am J Ophthalmol* 108:524–8, 1989
19. Friedberg ML, Pleyer U, Mondino BJ: Device drug delivery to the eye. *Ophthalmology* 98:725–32, 1991
20. Fyodorov SN, Ivashina AI, Bagrov SN, et al: Efficiency of collagen covers: application in cases in keratotomy, in: Fyodorov, SN (ed) *Eye Microsurgery*. Moscow, Research Institute of Eye Microsurgery, 1984
21. Gassett AR, Kaufman HE: Therapeutic uses of hydrophilic contact lenses. *Am J Ophthalmol* 69:252, 1970
22. Geasey SD, del Cerro M, DePaolis MD, et al: Collagen shields as a vehicle for collecting and studying migrating cells on human corneas. *Invest Ophthalmol Vis Sci* 33:298–303, 1992
23. Gipson IK, Westcott MJ, Brooksky NG: Effects of cytochalasins B and D and colchicine on migration of the corneal epithelium. *Invest Ophthalmol Vis Sci* 22:633, 1982
24. Glasser DB, Gardner S, Ellis JG: Loading doses and extended dosing intervals in topical gentamicin therapy. *Am J Ophthalmol* 99:329–32, 1985

25. Greggel HS, Friend J, Thoft RA: Collagen gel for ocular surface. *IOVS* 26: 901–5, 1985
26. Groden IR, White W: Porcine collagen corneal shield treatment of persistent epithelial defects following penetrating keratoplasty. *CLAO J* 16:95–7, 1990
27. Hillman JS, Marsters JB, Broad A: Pilocarpine-hydrophilic lenses in the management of acute glaucoma. *Trans Ophthalmol Soc UK* 95:79–84, 1975
28. Hobden JA, Reidy JJ, O'Callegan RJ, et al: Treatment of experimental *Pseudomonas* keratitis using collagen shields containing tobramycin. *Arch Ophthalmol* 106:1605–7, 1988
29. Holden BA, Mertz GW: Critical oxygen levels to avoid corneal edema for daily and extended wear contact lenses. *Invest Ophthalmol Vis Sci* 25:1161–7, 1984
30. Hull DS, Edelhauser HF, Hyndiuk RA: Ocular penetration of prednisolone and the hydrophilic contact lens. *Arch Ophthalmol* 92:413–6, 1974
31. Hwang DG, Stern WH, Hwang PH, MacGowan-Smith LA: Collagen shield enhancement of topical dexamethasone penetration. *Arch Ophthalmol* 107:1375–80, 1989
32. Kuwano M, Horibe Y, Kawashima Y: Effect of collagen cross-linking in collagen shields on ocular drug delivery. *J Ocular Pharmacol Ther* 13:31–40, 1997
33. Mahlberg K, Uusitalo RJ, Oksala O: Prevention of high risk graft rejection using cyclosporin A (CsA) incorporated into a collagen matrix. *Ocul Immunol Inflamm* 5:101–10, 1997
34. Marmer RH: Therapeutic and protective properties of the corneal collagen shield. *J Cataract Refract Surg* 14:496–9, 1988
35. Matoba AY, McCulley JP: The effect of therapeutic soft contact lenses on antibiotic delivery to the cornea. *Ophthalmology* 92:97–9, 1985
36. McCarey BE, Schmidt FH, Wilkinson KD, Baum JP: Gentamicin diffusion across hydrogel bandage lenses and its kinetic distribution on the eye. *Curr Eye Res* 3: 977–89, 1984
37. Meltzer MA, Nassif JM, Hyde KJ, Arthurs BP: Collagen shield contact lens use after eyelid surgery. *Ophthalm Plast Reconstr Surg* 8:290–1, 1992
38. Milani JK, Verbukh I, Pleyer U, et al: Collagen shields impregnated with gentamicin-dexamethasone as a potential drug delivery device. *Am J Ophthalmol* 116:622–7, 1993
39. Mindel JS, Friedman AH, Haimov T, et al: Eosinophil chemotaxis and anterior uveitis from topical dimaprit and nordimaprit. *Invest Ophthalmol Vis Sci* 27:1504–11, 1986
40. Mondino BJ: Collagen shields. *Am J Ophthalmol* 112:587–90, 1991
41. Murray TG, Jaffe GJ, McKay BS, et al: Collagen shield delivery of tissue plasminogen activator: functional and pharmacokinetic studies of anterior segment delivery. *Refract Corneal Surg* 8:44–8, 1992
42. Murray TG, Stern WH, Chin DH, MacGowan-Smith EA: Collagen shield heparin delivery for prevention of postoperative fibrin. *Arch Ophthalmol* 108:104–6, 1990
43. Nassaralla BA, Szerenyi K, Pinheiro MN, et al: Prevention of keratocyte loss after deepithelialization in rabbits. *Arch Ophthalmol* 113:506–11, 1995
44. Oakley DE, Weeks RD, Ellis PP: Corneal distribution of subconjunctival antibiotics. *Am J Ophthalmol* 81:307–12, 1976
45. O'Brien TP, Sawusch MR, Dick JD, et al: Use of collagen corneal shields versus soft contact lenses to enhance penetration of topical tobramycin. *J Cataract Refract Surg* 14:505–7, 1988
46. Petroustos G, Guimaraes R, Giraud J, Pouliquen Y: Antibiotics and corneal epithelial wound healing. *Arch Ophthalmol* 101:1775–8, 1983
47. Phinney RB, Schwartz S, Lee D, Mondino BJ: Collagen-shield delivery of gentamicin and vancomycin. *Arch Ophthalmol* 106:1599–604, 1988
48. Pleyer U, Legmann A, Mondino BJ, Lee DA: Use of collagen shields containing amphotericin B in the treatment of experimental *Candida albicans*-induced keratomycosis in rabbits. *Am J Ophthalmol* 113:303–8, 1992
49. Poland DE, Kaufman HE: Clinical uses of collagen shields. *J Cataract Refract Surg* 14:489–91, 1988
50. Praus R, Krejci L: Elution and intraocular penetration of the ophthalmic drugs of different molecular weights from the hydrophilic contact lenses through the intact and injured cornea. *Acta Univ Carol Med (Praha)* 23:3–10, 1977
51. Reidy JJ, Gebhardt BM, Kaufman HE: The collagen shield. A new vehicle for delivery of cyclosporin A to the eye. *Cornea* 9:196–9, 1990
52. Renard G, Bennans W, Lutaj P, et al: Comparative study of a collagen corneal shield and a subconjunctival injection at the end of cataract surgery. *J Cataract Refract Surg* 19:48–51, 1993
53. Ridley F: Therapeutic uses of scleral contact lenses. *Int Ophthalmol Clin* 2:697, 1969
54. Robin JB, Keys CL, Kaminski LA, Viana MA: The effect of collagen shields on rabbit corneal reepithelialization after chemical debridement. *Invest Ophthalmol Vis Sci* 31:1294–1300, 1990.
55. Ros FE, Tijn JW, Faber JAJ: Bandage lenses: collagen shield vs. Hydrogel lens. *CLAO J* 17:187–9, 1991
56. Ruffini JJ, Aquavella JV, Lo Cascio JA: Effect of collagen shields on corneal epithelialization following penetrating keratoplasty. *Ophthalmic Surg* 20:215, 1989
57. Sawusch MR, O'Brien TP, Dick JD, Gottsch JD: Use of collagen corneal shields in the treatment of bacterial keratitis. *Am J Ophthalmol* 106:279–81, 1988
58. Sawusch MR, O'Brien TP, Updegraff SA: Collagen corneal shields enhance penetration of topical prednisolone acetate. *J Cataract Refract Surg* 15:625–8, 1989
59. Schiff WM, Speaker MG, McCormick SA: The collagen shield as a collagenase inhibitor and clinical indicator of collagenase activity on the ocular surface. *CLAO J* 18:59–63, 1992
60. Schwartz SD, Harrison SA, Engstrom RE: Collagen shield delivery of amphotericin B. *Am J Ophthalmol* 109:701–4, 1990
61. Shaker CJ, Shunsuke U, Lo Cascio JA, Aquavella JV: Effect of collagen shield on cat corneal epithelial wound healing. *Invest Ophthalmol Vis Sci* 30:1565–8, 1989
62. Silbiger J, Stern GA: Evaluation of corneal collagen shields as a drug delivery device for the treatment of experimental *Pseudomonas* keratitis. *Ophthalmology* 99:889–92, 1992
63. Simsek NA, Manav Ay G, Tugal-Tutkun I: An experimental study on the effect of collagen shields and therapeutic contact lenses on corneal wound healing. *Cornea* 15:612–6, 1995
64. Stoop JW: Treatment of pressure sores in paraplegic patients with animal collagen. *Paraplegia* 8:177, 1970
65. Unterman SR, Rootman DS, Hill JM, et al: Collagen drug shield delivery: therapeutic concentrations of tobramycin in the rabbit cornea and aqueous humor. *J Cataract Refract Surg* 14:500–4, 1988
66. Wagoner MD, Kenyon KR, Gipson IK, et al: Polymorphonuclear neutrophils delay corneal epithelial wound healing in vitro. *Invest Ophthalmol Vis Sci* 25:1217–20, 1984
67. Wedge CI, Rootman DS: Collagen shields: efficacy, safety and comfort in the treatment of human traumatic corneal abrasion and effect on vision in healthy eyes. *Can J Ophthalmol* 27:295–8, 1992
68. Weissman BA, Lee DA: Oxygen transmissibility, thickness and water content of three types of collagen shields. *Arch Ophthalmol* 106:1706–8, 1988
69. Wentworth JS, Paterson CA, Wells JT: Collagen shields exacerbate ulceration of alkali-burned rabbit corneas. *Arch Ophthalmol* 111:389–92, 1993

The authors have no proprietary or commercial interest in any product or concept discussed in this article.

Reprint address: Mr CE Willoughby, Lecturer in Ophthalmology, University of Liverpool, Unit of Ophthalmology, Department of Medicine, University Clinical Departments, Duncan Building, Daulby Street, Liverpool L69 3GA, United Kingdom.