



New add-on intraocular lens for patients with age-related macular degeneration

Gabor B. Scharioth, MD, PhD

We present a new option for visual rehabilitation of patients with advanced macular degeneration and evaluate the outcomes in the first 8 patients who had implantation of the ciliary sulcus–fixated macular add-on intraocular lens (IOL) (Scharioth Macula Lens) at our institute. The surgical technique for implantation of the add-on IOL is described. Near vision improved in 7 eyes and was stable in 1 eye. The corrected near visual acuity improved by 4.4 lines with the macular add-on IOL at 15 cm versus with glasses at 40 cm; it improved by 2.1 lines with the macular add-on IOL at 15 cm versus with glasses at 15 cm. Distance vision was stable in all eyes. No intraoperative or postoperative complication occurred. The macular add-on IOL has the potential of improving near vision and reading ability in patients with advanced age-related macular degeneration.

Financial Disclosure: Dr. Scharioth is a consultant to Alcon Laboratories, Inc., and MediconTur Ltd. He is the inventor of the Scharioth Macula Lens and receives royalties.

J Cataract Refract Surg 2015; 41:1559–1563 © 2015 ASCRS and ESCRS

Age-related macular degeneration (AMD) has a high prevalence in industrialized societies and is the most common cause of loss of reading vision among patients older than 55 years.^{1,2} In recent years, major advances have been made in the therapy of the neovascular form of AMD,^{1,3,4} but reduced near visual acuity is still a major problem with all forms of AMD. External magnifying low visual aids have been available for decades, but use of them was uncomfortable and limited their acceptance. Various intraocular lenses (IOLs) or telescopic systems have been described but are not widely accepted because of the insufficient magnification, difficult surgical procedures, complication rate, high cost, and effect on distance visual acuity and/or visual field. Almost all solutions require phakic status of the eye and are implanted during cataract surgery.

A new macular add-on IOL (Scharioth Macula Lens A45SML, MediconTur Ltd.) was developed for visual rehabilitation of patients with advanced AMD. The design is based on an established concept for sulcus fixation in pseudophakic eyes. The A4W add-on IOL (1stQ GmbH) has been in clinical use for several years and has proven ease of implantation and a low complication rate.^{5,A}

SURGICAL TECHNIQUE

The macular add-on IOL is hydrophilic acrylic and designed for ciliary sulcus implantation in pseudophakic eyes. It has a central portion of 1.5 mm diameter with an addition of +10 diopters (D) (Figure 1). The mathematically calculated magnification is about 2.0, but this is dependent on the anatomy of the eye and the final reading distance. The remaining optical zone is refractory neutral. The overall diameter of the IOL is 13.0 mm with 4 symmetric haptics. The IOL can be implanted simultaneously during uncomplicated standard phacoemulsification with in-the-bag posterior chamber IOL (PC IOL) implantation or years after cataract surgery. It has the Conformité Européenne mark (not U.S. Food and Drug Administration approved) and is patent pending.

A minimum incision of 2.2 mm is required. The anterior chamber is filled with an ophthalmic viscosurgical device (OVD). The macular add-on IOL is placed in the cartridge carefully so the IOL optic folds upward

Submitted: November 2, 2014.

Final revision submitted: March 31, 2015.

Accepted: March 31, 2015.

From Aurelios Augenzentrum, Recklinghausen, Germany, and the Department of Ophthalmology, University of Szeged, Szeged, Hungary.

Corresponding author: Gabor B. Scharioth, MD, PhD, Aurelios Augenzentrum, Erlbruch 34-36, 45657 Recklinghausen, Germany. E-mail: gabor.scharioth@augenzentrum.org.



Figure 1. Image of macular add-on IOL.

during folding of the cartridge's winglets. This results in controlled intraocular unfolding during implantation. While the plunger of the injector is pushed, a second instrument is used through the side-port incision to guide the leading haptic into the ciliary sulcus (Figure 2). The trailing haptics are usually placed in the ciliary sulcus in a second step. Proper positioning of the haptics and IOL centration are checked (Figure 3). Finally, the OVD is removed and the incisions are hydrated to prevent leakage.

RESULTS

The macular add-on IOL was implanted in the better-seeing eye in 8 patients. The preoperative corrected

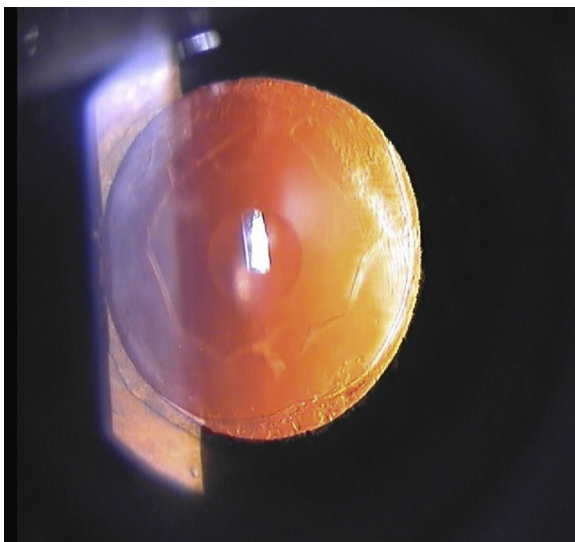


Figure 3. Postoperative photograph in retroillumination. Note the central portion of the macular add-on IOL status after neodymium: YAG laser capsulotomy.

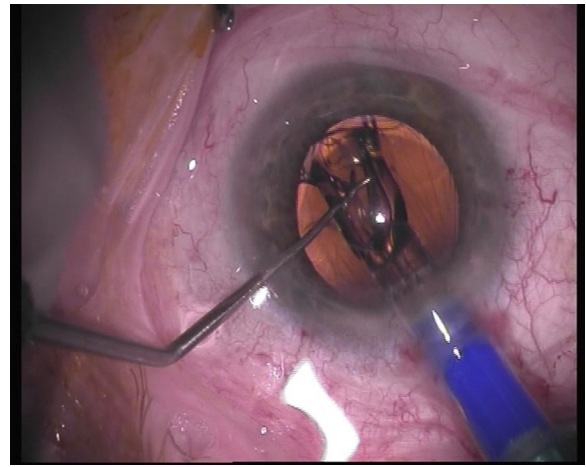


Figure 2. Intraoperative view during implantation of macular add-on IOL. The IOL is unfolding while an instrument through the side-port incision is guiding the leading haptic into the ciliary sulcus.

distance visual acuity (CDVA) in the patients was between 0.05 and 0.4. Implantation was uneventful in all cases, and no intraoperative or postoperative complications occurred. No patient complained of visual phenomenon such as halos, reduced visual field, or diplopia.

Visual acuity was tested preoperatively and 4 weeks postoperatively for distance and near with correction. The Radner chart (Radner Lesetafel, Norbert Werner GmbH) in German⁶ was used to test reading vision. In all patients but 1, the uncorrected near visual acuity (UNVA) at 15 cm and the corrected near visual acuity (CNVA) improved. The patient without improvement had advanced AMD with a large area of retinal pigment epithelial atrophy of the posterior pole and a preoperative CDVA of 0.05 (Table 1). In all other patients, the CNVA improved by 4.4 lines with the macular add-on IOL at 15 cm versus with +2.5 D correction at 40 cm; it improved by 2.1 lines with the macular add-on IOL at 15 cm versus with +6.0 D correction at 15 cm.

Excluding the eye with advanced AMD, the results were better. The CNVA improved by 5.0 lines with the macular add-on IOL at 15 cm versus with +2.5 D correction at 40 cm; it improved by 2.4 lines with the macular add-on IOL at 15 cm versus with +6.0 D correction at 15 cm. No patient had a postoperative decrease in CDVA. The postoperative ability to visualize the fundus, take fundus photographs, and perform optical coherence tomography (OCT) was not affected.

DISCUSSION

The new IOL was developed to achieve sufficient magnification at a reduced reading distance to

Table 1. Preoperative and postoperative distance and near visual acuity in first 8 patients with macular add-on IOL implantation.

Patient	Pre CDVA	Post CDVA	Pre CNVA @ 40 cm (+2.5 D)	Pre CNVA @ 15 cm (+6.0 D)	Post UNVA @ 15 cm (Macular Add-on IOL)
1	0.4	0.4	0.32	0.5	1.0
2	0.12	0.12	0.064	0.1	0.2
3	0.4	0.4	0.4	0.64	1.0
4	0.05	0.05	0.064	0.064	0.064
5	0.16	0.16	0.1	0.2	0.4
6	0.2	0.2	0.1	0.2	0.5
7	0.1	0.1	0.1	0.2	0.26
8	0.5	0.5	0.26	0.5	0.64

CDVA = corrected distance visual acuity; CNVA = corrected near visual acuity; IOL = intraocular lens; UNVA = uncorrected near visual acuity

improve near vision in patients with advanced AMD and pseudophakic lens status. The distance visual acuity (Table 1) and visual field were not to be affected, and the implantation technique was safe and had a short learning curve.

The first results of implantation of the macular add-on IOL showed impressive improvement in UNVA in patients with AMD. Most patients could read newspaper text (UNVA 0.4, Radner 5, or better). Only 1 patient with excessive atrophy of the posterior pole experienced no improvement in near vision. To my knowledge, this is the first intraocular magnifying IOL for improving UNVA that can be implanted during cataract surgery or years after without the need to explant the in-the-bag PC IOL. The implantation technique for this IOL is easier than that for previous IOLs through an incision smaller than 3.0 mm. The Lipshitz implantable miniaturized telescope (Visioncare Ophthalmic Technologies, Inc.) was introduced about 10 years ago,⁷⁻⁹ and the concept of the mini telescope^B (iolAMD, London Eye Hospital Pharma) was recently presented. The Lipshitz implantable miniaturized telescope requires a large incision of at least 8.0 mm and should be implanted in the capsular bag. The large incision could cause increased corneal astigmatism and the risk for complications. However, the Lipshitz implantable miniaturized telescope was not designed for piggyback implantation and there is no long-term experience in adding this thick device to an in-the-bag PC IOL. The mini telescope requires simultaneous implantation of 1 IOL in the capsular bag and a second IOL in the ciliary sulcus. Therefore, it is not appropriate for pseudophakic patients.

In my experience, a large number of patients with advanced AMD are pseudophakic and do not benefit from these options. Agarwal et al.^C report initial results of 3 patients with piggyback implantation of a variation of the Lipshitz implant (Orilens,

Optolightvision Technology) with no complications. The implant has a central thickness of about 1.25 mm and requires a minimum incision of 6.0 mm for implantation. This might increase the risk for direct contact with the other IOL and for interlenticular secondary cataract (Figure 4). The macular add-on IOL has the advantage that it can be implanted during or after cataract surgery and the required incision size is only 2.2 mm. The IOL is specially designed for add-on sulcus implantation and has a proven low complication rate.^{5,A} Theoretically, there seems to be less dependence on perfect centration than with other implants with a Galilean telescope and/or prism. The advantage of devices with a Galilean telescope is possible improvement in distance vision, but the devices severely affect the peripheral vision and visual field. The reduced amount of light might affect patients in low lighting settings. Therefore, these devices may not be implanted in single-eyed patients. Depth of focus might be affected from the loss of binocularity.^D The macular add-on IOL does not affect the peripheral vision and does not reduce binocularity at normal

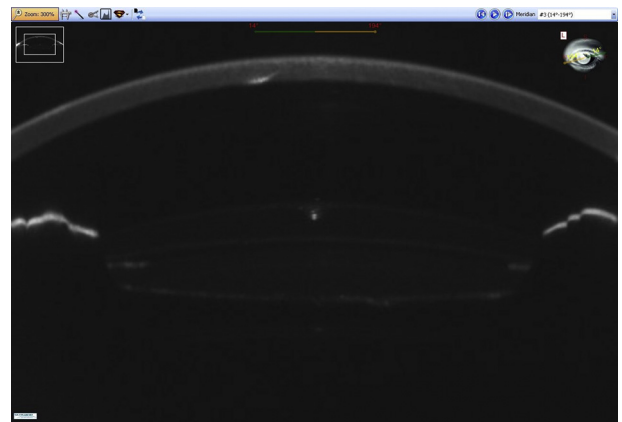


Figure 4. Scheimpflug image of the anterior segment after ciliary sulcus implantation of the macular add-on IOL in a pseudophakic eye. Note the space between the 2 IOLs.

reading distance. Binocularity is reduced only at a reading distance of 15 cm. At this distance, the image of the other eye will be blurry and not cause diplopia.

The CNVA was better after implantation of the macular add-on IOL at 15 cm than with the preoperative CNVA with +6.0 D at 15 cm. I believe this is explained by the fundamental optical principles that image quality is improved with the IOL implanted in the eye rather than placed externally and that the image quality is also better if the IOL is placed close to the optical aperture. This is especially true if the pupil is small, as in near miosis. Furthermore, I believe that sporadic use of +6.0 D eyeglasses may not be comparable to the permanent condition after implantation of the macular add-on IOL. Furthermore, near vision improved over the first 4 postoperative weeks. This could be the result of a training effect and adaptation to the new condition.

Possible contraindications to implantation of the macular add-on IOL are status after complicated cataract surgery (eg, aphakia, sulcus implanted PC IOL), excessive zonular weakness (eg, excessive pseudoexfoliation syndrome, zonular dialysis, pseudophacodonesis), excessive secondary cataract, chronic uveitis, active rubeosis iridis, central corneal opacities, and inability to understand the principle of this implant (reduced reading distance, maximum magnification). The macular add-on IOL has the potential to improve near vision and reading ability in patients with advanced AMD. Based on our initial experience, a minimum CDVA of 0.1 is recommended to achieve sufficient results. Preoperative testing of CNVA at 40 cm versus 15 cm provides valid information about the potential of the macular add-on IOL; if CNVA is better at 15 cm and the patient is motivated, he or she might be a good candidate. In the future, other preoperative testing such as microperimetry, spectral domain OCT, and pupillometry might also be used for proper patient selection. Further studies are needed to evaluate the best candidates for implantation of the macular add-on IOL and other indications for its use, such as diabetic or myopic maculopathy.

WHAT WAS KNOWN

- Magnification could improve near vision and reading ability in patients with AMD.

WHAT THIS PAPER ADDS

- A specially designed IOL with a central magnifying portion implanted in the ciliary sulcus of pseudophakic eyes can improve near vision in patients with AMD.

REFERENCES

1. Comparison of Age-Related Macular Degeneration Treatments Trials (CATT) Research Group. Writing committee: Martin DF, Maguire MG, Fine SL, Ying GS, Jaffe GJ, Grunwald JE, Toth C, Redford M, Ferris FL III. Ranibizumab and bevacizumab for treatment of neovascular age-related macular degeneration; two-year results. *Ophthalmology* 2012; 119:1388–1398. Available at: <http://www.ncbi.nlm.nih.gov/pmc/articles/PMC3389193/pdf/nihms373947.pdf>. Accessed May 15, 2015
2. The Eye Diseases Prevalence Research Group. Causes and prevalence of visual impairment among adults in the United States. *Arch Ophthalmol* 2004; 122:477–485. Available at: <http://archophth.jamanetwork.com/data/Journals/OPHTH/9922/EEB30081.pdf>. Accessed May 15, 2015
3. Rosenfeld PJ, Brown DM, Heier JS, Boyer DS, Kaiser PK, Chung CY, Kim RY; for the MARINA Study Group. Ranibizumab for neovascular age-related macular degeneration. *N Engl J Med* 2006; 355:1419–1431. Available at: <http://www.nejm.org/doi/pdf/10.1056/NEJMoa054481>. Accessed May 15, 2015
4. Heier JS, Brown DM, Chong V, Korobelnik J-F, Kaiser PK, Nguyen QD, Kirchhof B, Ho A, Ogura Y, Yancopoulos GD, Stahl N, Vitti R, Berliner AJ, Soo Y, Anderesi M, Groetzsch G, Sommerauer B, Sandbrink R, Simader C, Schmidt-Erfurth U; for the VIEW 1 and VIEW 2 Study Groups. Intravitreal aflibercept (VEGF trap-eye) in wet age-related macular degeneration. *Ophthalmology* 2012; 119:2537–2548
5. Sauder G, Cordes A. Scope of applications and experience record with a new generation of add-on IOLs: the A4W lens. *Ophthalmol-Chirurgie* 2012; 24(suppl. 2):1–6. Available at: http://www.1stq.de/media/raw/A4W_Englisch_AddOn_Ophthalmol-Chirurgie_engl.pdf. Accessed May 15, 2015
6. Radner W, Willinger U, Obermayer W, Mudrich C, Velikay-Parel M, Eisenwort B. Eine neue Lesetafel zur gleichzeitigen Bestimmung von Lesevisus und Lesegeschwindigkeit [A new reading chart for simultaneous determination of reading vision and reading speed]. *Klin Monatsbl Augenheilkd* 1998; 213:174–181
7. Lipshitz I, Loewenstein A, Reingewirtz M, Lazar M. An intraocular telescopic lens for macular degeneration. *Ophthalmic Surg Lasers* 1997; 28:513–517
8. Lane SS, Kuppermann BD, Fine IH, Hamill MB, Gordon JF, Chuck RS, Hoffman RS, Packer M, Koch DD. A prospective multicenter clinical trial to evaluate the safety and effectiveness of the implantable miniature telescope. *Am J Ophthalmol* 2004; 137:993–1001
9. Agarwal A, Lipshitz I, Jacob S, Lamba M, Tiwari R, Kumar DA, Agarwal A. Mirror telescopic intraocular lens for age-related macular degeneration; design and preliminary clinical results of the Lipshitz macular implant. *J Cataract Refract Surg* 2008; 34:87–94

OTHER CITED MATERIAL

- A. Scharioth GB, "Add-on IOLs for Vitrectomized Silicone Oil-Filled Eyes," *Retinal Physician* May 2014; 11:31–33. Available at: <http://www.retinalphysician.com/articleviewer.aspx?articleID=111129>. Accessed May 15, 2015
- B. Artal P, Tabernero J, Robbie SJ, Qureshi BA. Intraocular mini-telescope for AMD patients. *IOVS* 2014; 55:E-Abstract 4133. Available at: <http://iovs.arvojournals.org/article.aspx?articleid=2269613&resultClick=1>. Accessed May 15, 2015
- C. Agarwal A, Lipshitz I, Jacob S, "Sulcus-Implanted Mirror Telescopic IOL Helpful for AMD and Other Macular Disorders,"

Ocular Surgery News U.S. Edition, April 10, 2011. Available at: <http://www.healio.com/ophthalmology/retina-vitreous/news/print/ocular-surgery-news/%7B69de719e-39b7-4c13-b006-fab76a6a24fd%7D/sulcus-implanted-mirror-telescopic-iol-helpful-for-amd-other-macular-disorders>. Accessed May 15, 2015

D. Visioncare Ophthalmic Technologies. Implantable miniature telescope. Patient information booklet. Available at: http://www.fda.gov/ohrms/dockets/ac/06/briefing/2006-4225b1_06_Patient%20Information%20Brochure%2001%2024%2006.pdf. Accessed May 15, 2015