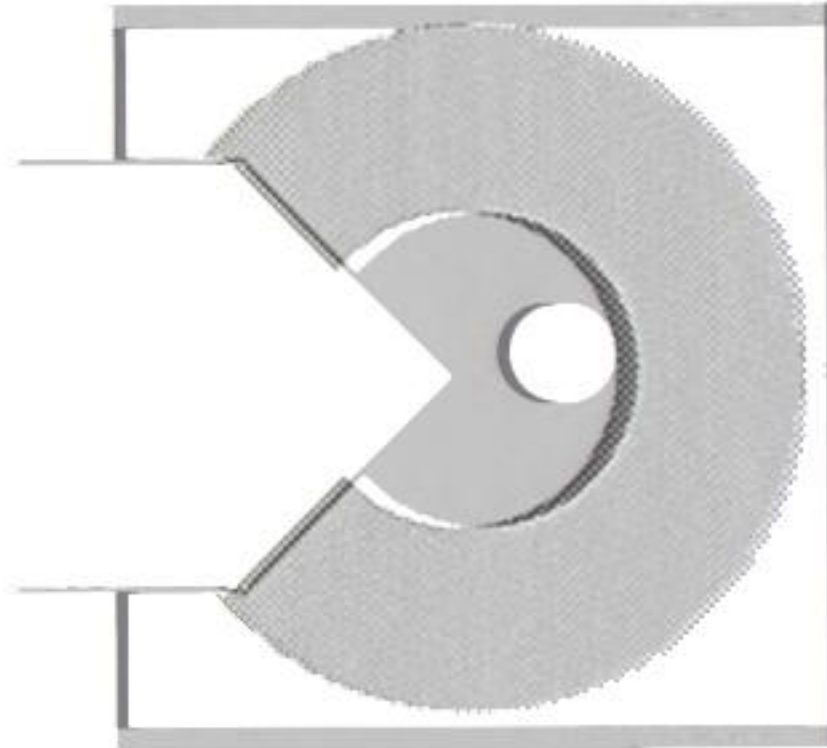


24 months results of the comparative study Medicontur hydrophobic and Alcon Acrysof



Gábor B. Scharioth

Augenzentrum Recklinghausen, Germany

University of Szeged, Hungary

Purpose

To evaluate the PCO rate after one year of hydrophobic single piece IOL

360° sharp edge (Z-Flex 860FAB, Medicontur, Hungary)

vs.

interrupted sharp edge design (Acrysof SA60AT, Alcon, USA)

a prospective intraindividual and interindividual study was performed.

Z Flex 860FAB,
Medicontur, Hungary


hydrophobic acrylic material
single piece

aspheric, cornea optimized

360° sharp edge

UV absorber (blue filter available)

6.0mm optic diameter



Acrysof SA60AT,
Alcon, USA

hydrophobic acrylic material
single piece

spheric

interrupted sharp edge

UV absorber (blue filter available)

6.0mm optic diameter

Method / Study design

Standard phacoemulsification with in-the-bag implantation
by an experienced surgeon GS

seventy eyes of 35 patients (10 male, 25 female)

Special care to clean the capsular bag from all cortex fibers and that the
capsulorrhexis was circular overlapping the IOL optic

Z Flex 860 FAB or Acrysof SA60AT was implanted

The surgeon was informed about the IOL type only after completed
irrigation aspiration.

Postoperative care prednisolone acetate 1% 4x daily for 4 weeks

At 12 and 24 months postoperative all eyes were controlled and a photo in
retroillumination was made to estimate the PCO.

Z Flex 860 FAB Medicontur

stiff material

easy implantation

excellent stabilization

- very good centration

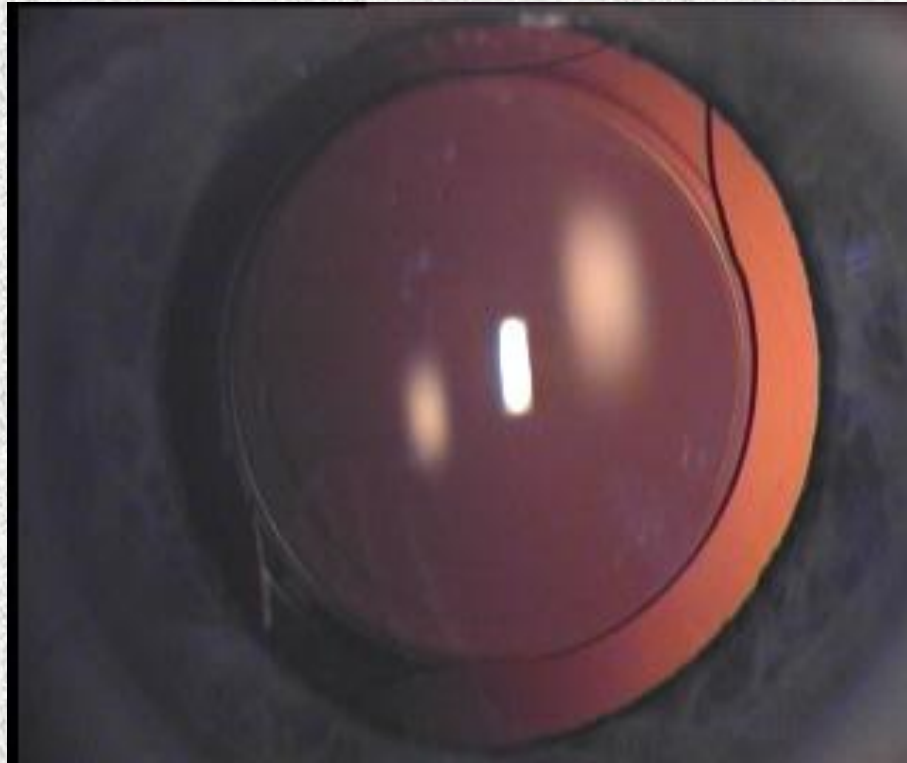
- no button holing

- no iris capture

very clear optic

- no opacification

- no glistening



No intra- or postoperative lens related complication occurred

Acrysof SA60AT Alcon

less stiff material

easy implantation

excellent stabilization

- very good centration

- no button holing

- no iris capture

very clear optic

- no opacification

- minimal glistening



No intra- or postoperative lens related complication occurred

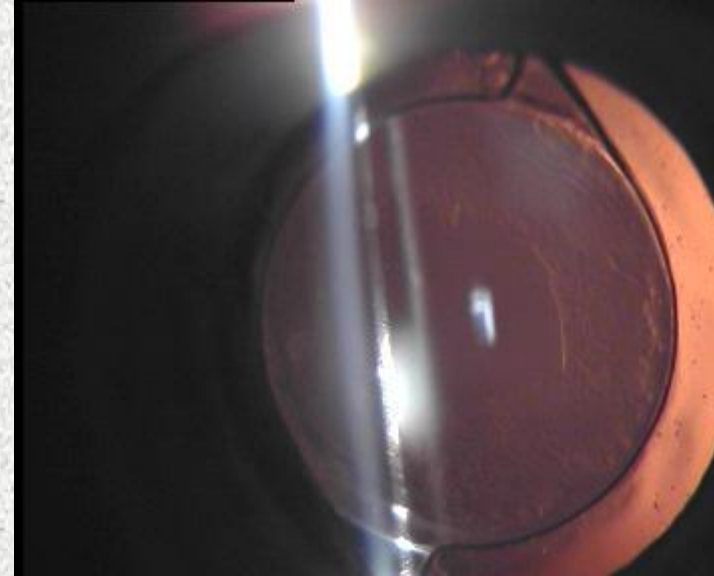
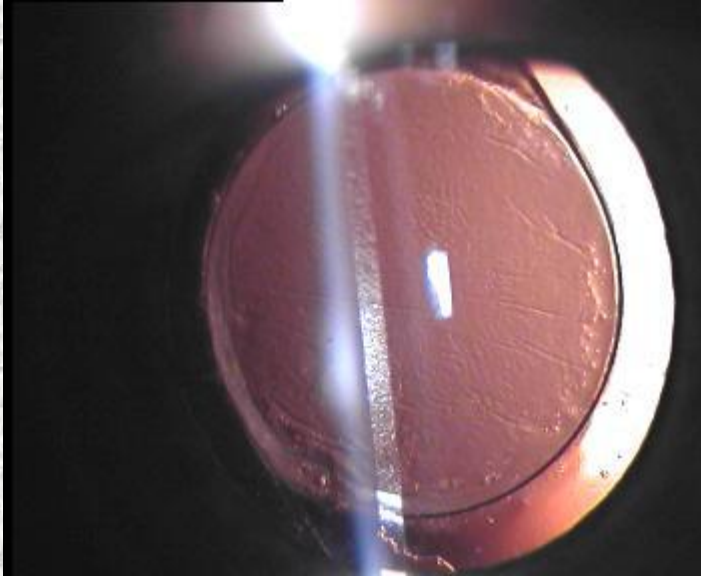
Acrysof SA60AT Alcon

One eye with excessive PCO

BCVA 0.32

NdYAG Laser performed

BCVA increased to 1.0





Results


	Alcon Acrysosof	Medicontur Z Flex
PCO inside optic		
12 months	8	0
24 months	16	16
YAG capsulotomy		
12 months	1	0
24 months	5	3

PCO rate at 12 months and YAG capsulotomy rate at 24 months show significant difference.

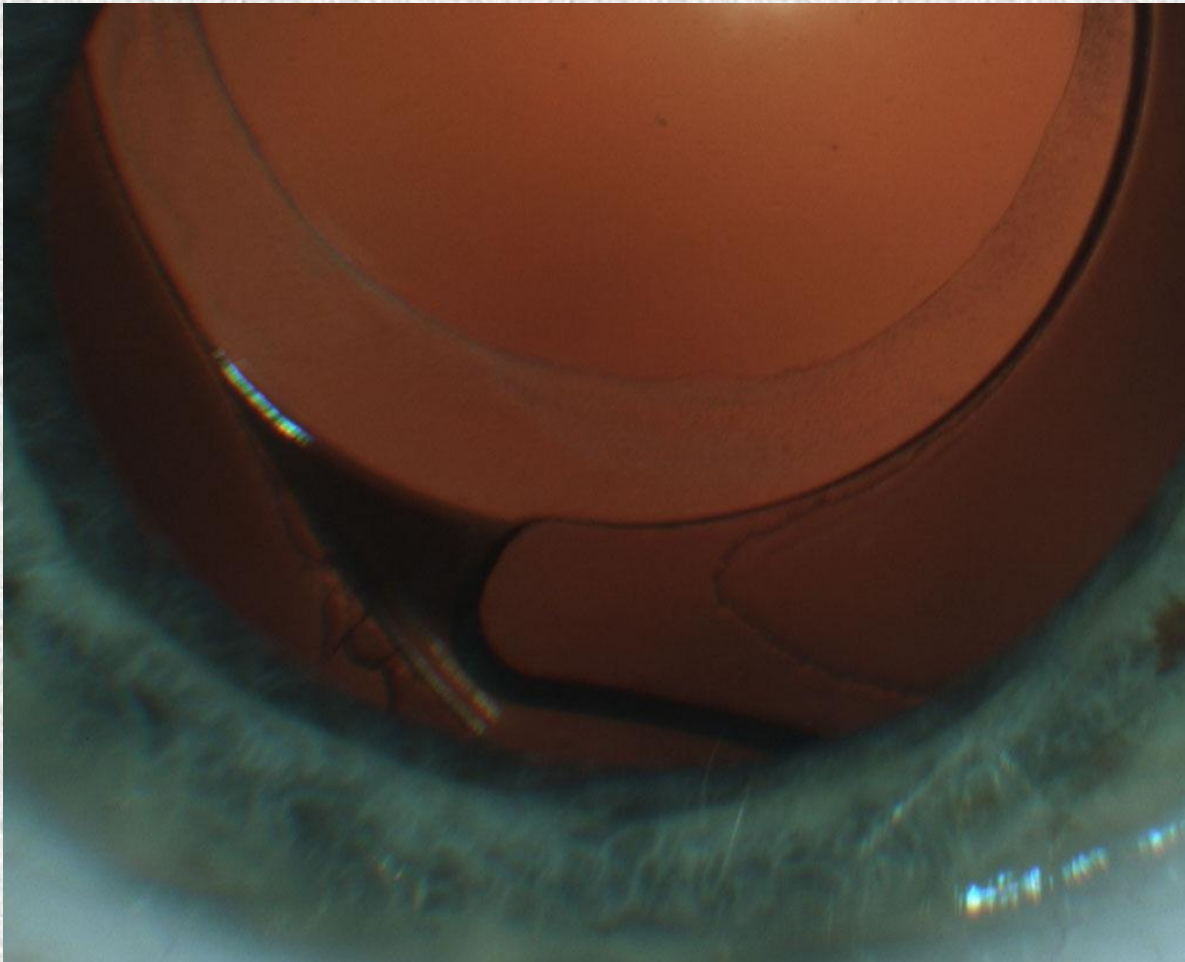
Optic Haptic Junction



Optic Haptic Junction



Optic Haptic Junction



Acrysof

If IOL haptic is fixed in equator during capsular bag shrinkage it will rotate





Image from primary study on Alcon Acrysof single piece IOL

Acrysof

If IOL haptic is fixed in equator during capsular bag shrinkage it will rotate

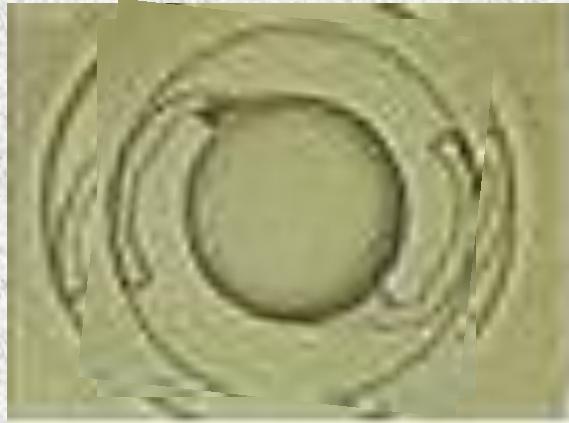



Image from primary study on Alcon Acrysof single piece IOL

IOL Rotation



IOL Rotation could cause PCO in IOL with interrupted posterior sharp edge

IOL Rotation and PCO

IOL Rotation could cause PCO in IOL with interrupted posterior sharp edge



because:

- space is created at the optic haptic junction
- this funnel guides lens epithelial migration towards the IOL optic
- lens epithelial cells become located at the optic haptic junction

Conclusion

Today phacoemulsification with in-the-bag implantation of a single piece IOL is standard of care in most parts of the world.

Hydrophobic material and sharp edge design of the optics have proven to lower the PCO rate after in-the-bag implantation with overlapping rhexis.

We found a tendency of ingrowth of lens epithelial cells at the optic-haptic junction and higher PCO rate in IOL with interrupted sharp edge design.

Multiple eyes showed IOL rotation with IOL with interrupted sharp edge design.

As PCO development is a continuous process, longer follow-up is recommended and may prove a significant difference between the different IOL designs.