

# The Current Situation in Non-penetrating Glaucoma Surgery

a report by

**Efstratios Mendrinios and Tarek Shaarawy**

Department of Ophthalmology, Glaucoma Unit, University of Geneva

DOI: 10.17925/EOR.2009.02.01.35

The concept of non-penetrating glaucoma surgery (NPGS) originated in 1964 when Krasnov published his first report on sinusotomy.<sup>1</sup> This operation consisted of removing a lamellar band of the sclera, opening the Schlemm's canal over 120° from 10 to two o'clock. The inner wall of the Schlemm's canal was untouched and the conjunctiva was closed. However, sinusotomy never became popular because it was a difficult operation, it needed a surgical microscope and the Schlemm's canal had to be found, which is not easy.

In the late 1960s and for the next three decades, trabeculectomy, as described by Sugar<sup>2</sup> in 1961 and Cairns<sup>3</sup> in 1968, became the gold standard technique for filtering surgery. However, even with the numerous modifications proposed to the original trabeculectomy, several surgeons reconsidered Kraznov's work because of the lack of a reproducible post-operative intraocular pressure (IOP) reduction and the early post-operative complications, which were mainly related to the penetration of the anterior chamber with sudden decompression of the eye.

Several techniques of non-penetrating filtering surgery based on sinusotomy have been described. As the main aqueous outflow resistance is located at the juxtacanalicular trabeculum and the inner wall of the Schlemm's canal, these two anatomical structures were targeted. Non-penetrating trabeculectomy was proposed by Zimmerman<sup>4</sup> in 1984 and Arenas first coined the term *ab externo* trabeculectomy in 1991.<sup>5</sup> Fyodorov encouraged the removal of the corneal stroma behind the anterior trabeculum and the Descemet's membrane, and called this deep sclerectomy (DS).<sup>6</sup> This was also described by Kozlov<sup>7</sup> and later by Stegmann.<sup>8</sup> Currently, DS with *ab externo* trabeculectomy and viscocanalostomy (VCS) are the most commonly used non-penetrating procedures.

## Principles of Non-penetrating Glaucoma Surgery – Deep Sclerectomy and Viscocanalostomy

The principal common concept of NPGS is to create filtration through a naturally occurring membrane that acts as an outflow resistance site, allowing a progressive decrease in IOP and avoiding post-operative ocular hypotony, without penetration into the anterior chamber. This membrane, the trabeculo-Descemet's membrane (TDM), consists of the anterior trabecular meshwork and the peripheral Descemet's membrane. To expose the membrane, a deep sclerokeratectomy should be performed, providing a post-operative intrascleral space; the juxtacanalicular trabeculum and Schlemm's canal endothelium are then removed (see *Figure 1*). The intrascleral space may act as an aqueous reservoir and as a filtration site that may reduce the need for a large subconjunctival filtration bleb, therefore reducing the risk of late bleb-related complications. The main disadvantage of both DS and VCS is that they are associated with a long and demanding learning curve.

Stegmann et al.<sup>8</sup> described a variant of NPGS and termed it VCS to emphasise the importance of injecting high-viscosity sodium hyaluronate into the Schlemm's canal as a means of improving aqueous drainage by this route. *In vivo* primate<sup>9,10</sup> and human eye<sup>9</sup> studies reported that an injection of viscoelastic material in Schlemm's canal resulted not only in dilatation of the canal and associated collector channels, but also in focal disruptions of the inner wall endothelium of the Schlemm's canal and disorganisation of the juxtacanalicular zone. This resulted in direct communication of the juxtacanalicular zone extracellular spaces with the lumen of the Schlemm's canal. This may initially enhance conventional aqueous outflow,<sup>9</sup> accounting for an approximately 30% increase in the outflow facility in non-human primates.<sup>10</sup> Any disruption of the posterior wall of the Schlemm's canal may also provide direct communication between its lumen and the tissues of the ciliary body, thereby enhancing uveoscleral outflow.<sup>9</sup>

## Alternative New Techniques

Recently, some authors have reported on the use of different kinds of laser to ablate the deep scleral tissue. As the wavelength of the erbium: yttrium–aluminium–garnet (Er:Yag) laser is near the maximum absorption limit of water, the ablation is self-limited by the percolation of the aqueous humour. The mean IOP reduction following Er:Yag laser varies between 35 and 53% and complete success rates between 37.5 and 85%.<sup>11–13</sup> Experimental and clinical studies using the excimer, CO<sub>2</sub> and femtosecond laser have also reported encouraging preliminary results.<sup>14–18</sup> No comparative study between laser-assisted DS and trabeculectomy are available yet. Further studies and longer follow-ups are necessary for the

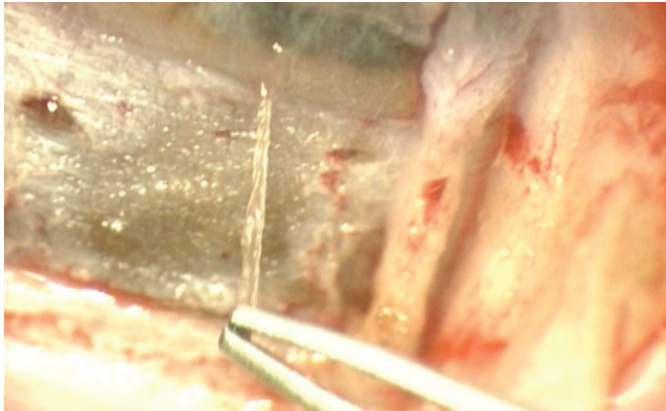


Efstratios Mendrinios is a Resident in the Department of Ophthalmology at the University of Geneva. He is a member of the American Academy of Ophthalmology (AAO) and the Association for Research in Vision and Ophthalmology (ARVO). He has authored or co-authored over 30 scientific papers and book chapters related to ophthalmic topics. His main fields of clinical and research interest focus on non-penetrating glaucoma surgery techniques and vascular pathologies of the optic nerve and of the retina. Dr Mendrinios obtained his medical degree from the University of Liège.



Tarek Shaarawy is Head of the Glaucoma Department at the University of Geneva. He is Secretary General of the International Society of Glaucoma Surgery and Associate Executive Vice President of the World Glaucoma Association (WGA). He has practised eye surgery in Egypt, Switzerland, Saudi Arabia, the Democratic Republic of Congo, Zambia and Ethiopia, among other countries. His main research interest is the promotion of new surgical techniques for glaucoma surgery. Dr Shaarawy has written or edited five textbooks, more than 20 book chapters and 30 articles in peer-reviewed journals.

E: tarek.shaarawy@hcuge.ch

**Figure 1: Deep Sclerectomy with *Ab Externo* Trabeculectomy**

*Under the superficial scleral flap, a deep corneosclerotomy unroofing the Schlemm's canal has been performed and the deep scleral flap has been removed. Now a clear membrane can be seen, consisting of the floor of the Schlemm's canal (opaque band) and Descemet's membrane (transparent segment). The juxtacanalicular trabeculum and inner wall of the Schlemm's canal can be grabbed with a blunt forceps and peeled easily by pulling on them.*

evaluation of the efficacy of laser-assisted DS as an alternative to the conventional surgical procedure.

### The Use of Implants

To avoid secondary collapse of the superficial flap, a space maintainer implant is placed in the scleral bed. The first to be used was the collagen Aquaflo implant (STAAR, Collagen Glaucoma Drainage Device, STAAR, Surgical AG Nidau, Switzerland),<sup>19,20</sup> a highly purified porcine collagen dehydrated into a cylinder (4x1x1mm). It swells rapidly once exposed to the aqueous humour and is resorbed within six to nine months after surgery.<sup>21</sup> Another device that has been proposed to maintain the intrascleral space is the reticulated hyaluronic acid implant (SK-GEL, Corneal Laboratories, Paris, France), which is an equilateral triangle 3.5mm long and 500µm thick or an isosceles triangle of 4.5x3mm at the same thickness.<sup>22</sup> The advantage of this implant is that it occupies a large volume in the filtration area while allowing for sufficient circulation of the aqueous humour, and it does not need to be sutured at the sclera. More recently, a hydrophilic acrylic implant (T-flux implant, IOLTech Laboratories, La Rochelle, France) that is non-absorbable has been developed.<sup>23</sup> It is a T-shaped implant that creates an evacuating canal along the foot and each arm of the T shape and is inserted into one of the surgically created openings of the Schlemm's canal. New implants have been developed in the past few years with promising results, such as the 2-hydroxyethyl-hethacrylate (HEMA) implant (Esnoper, AJL Ophthalmics, SA, Miñano, Alava, Spain)<sup>24</sup> and a cross-shaped rigid non-absorbable implant made of poly-methyl-methacrylate (PMMA) (HOMDEC SA, Belmont, Switzerland).<sup>25</sup> Other low-cost implants such as chromic suture material<sup>26</sup> and autologous scleral implant<sup>27</sup> have been used in deep sclerectomy. Amniotic membrane has also been tried as an implant.<sup>28</sup> Further studies are needed to evaluate the role of these implants.

### Neodymium-doped:Yttrium–Aluminium–Garnet Goniopuncture

When filtration through the TDM is considered to be insufficient because of elevated IOP, neodymium-doped (Nd):YAG goniopuncture can be performed. An insufficient surgical dissection can be the reason for elevated IOP in the first post-operative period or fibrosis of the TDM if it is required later than approximately nine months, and may lead to a flattened bleb. Using a gonioscopy contact lens, the aiming beam is focused in the semi-transparent TDM. Using the free-running Q switched

mode with a power of 5–10mJ, two to 15 shots are applied, resulting in the formation of microscopic holes through the TDM and allowing the direct passage of aqueous from the anterior chamber to the intrascleral space. In their studies on results of DS, Shaarawy et al. performed goniopuncture in 42–46% of their patients who had undergone DS without implant and in 46–51% of those who had undergone DS with collagen implant (DSCI).<sup>29–31</sup> The immediate success rate was 91.6%.<sup>31</sup> In their study on results of VCS,<sup>32</sup> 37% of their patients needed goniopuncture post-operatively to control raised IOP. Overall, the rate of goniopuncture after DS (with or without implant and/or antimetabolites) ranges between 4.6 and 81%, with an IOP reduction as high as 45%; the rate of goniopuncture after primary VCS varies ranges between 4.1 and 56%, with an IOP reduction as high as 38.2%.<sup>33</sup>

### Indications and Contraindications of Non-penetrating Glaucoma Surgery

NPGS targets the presumed site of pathology in primary open-angle glaucoma (OAG), namely the trabecular meshwork.<sup>34</sup> The site of aqueous outflow resistance is presumed to be the juxtacanalicular trabeculum, the inner wall of the Schlemm's canal and the endothelial lining. Scraping, thinning out and peeling the posterior trabeculum improve filtration. In NPGS, DS and *ab externo* trabeculectomy are both necessary to obtain an optimal decrease in outflow resistance. NPGS has the advantage of being less cataractogenic than trabeculectomy and ideally should be considered as a safer option in phakic patients with primary OAG. It is an efficient surgery in medically uncontrolled primary OAG.<sup>35</sup> It appears to offer glaucoma patients with high myopia a safe filtering procedure,<sup>31</sup> is a safe and valuable option in patients with pseudoexfoliative glaucoma<sup>36</sup> and seems especially appropriate in these patients, given the increased permeability of the blood–aqueous barrier as well as the higher risk of complications with intraocular surgery. NPGS is a potential therapy for pigmentary glaucoma also. It targets the site of pathology – the pigment-loaded trabecular meshwork – which can be reconditioned to establish filtration. In uveitic glaucoma cases NPGS is associated with less post-operative inflammation.<sup>37–39</sup> Moreover, NPGS may be indicated in some cases of congenital, juvenile and aphakic glaucoma when the irido-corneal angle is not severely distorted.<sup>40–45</sup> If not sufficient, it can be associated with other *ab externo* procedures and/or with laser or medical treatment. Converting to penetrating surgery may be necessary in refractory cases. There are no published reports on NPGS in primary-angle closure glaucoma. This is not surprising considering the principles of function of NPGS. Likewise, secondary angle closure aetiological entities are a relative contraindication. However, the decision depends on the degree of angle closure. Neovascular glaucoma is an absolute contraindication because new blood vessels invade the iridocorneal angle and the trabeculum loses its filtering function because of the neovascularisation, providing little chance of surgical success.

### Complications of Non-penetrating Glaucoma Surgery

There is an agreement among published reports that NPGS offers a lower rate of complications compared with conventional trabeculectomy, with or without antimetabolites. This is largely due to the fact that the eye is not fully penetrated as with trabeculectomy, and that the aqueous is percolated through the remaining TDM, thus preventing a sudden intra- and post-operative hypotony. Moreover, visual acuity is generally preserved after NPGS and returns to the pre-operative level within the first post-operative week.<sup>46</sup> Complications of NPGS can be intraoperative, i.e. rupture of the TDM,<sup>47</sup> early post-operative or late post-operative. Long-standing hypotonia, hypotonic maculopathy, flat anterior chamber, choroidal detachment and

suprachoroidal haemorrhage are rare difficulties,<sup>8,20,47–49</sup> whereas they are potentially sight-threatening complications following trabeculectomy. Similarly, blebitis is a well-known and potentially dangerous complication after trabeculectomy, and can lead to endophthalmitis.<sup>50</sup> In NPGS, the TDM offers a barrier against the intraocular spread of bacteria. Blebitis and infectious keratitis are rare complications.<sup>47,51,52</sup> Cataract progression is less influenced by DS compared with trabeculectomy. The Advanced Glaucoma Intervention Study (AGIS) estimated that the rate of cataract formation after the first trabeculectomy is 78% at five years. The risk of cataracts is doubled if there is a significant post-operative inflammation or a flat anterior chamber.<sup>53</sup> Shaarawy et al.<sup>29</sup> followed 105 patients for a mean of 64 months and showed progression of existing age-related cataracts in 25% of eyes, but no surgery-induced cataracts. Wound leaks or a positive Seidel test occur more often after trabeculectomy than after NPGS. In a two-year prospective study on bleb characteristics of 125 eyes that had mitomycin-C-augmented glaucoma surgery, bleb leaks were more frequently observed in the trabeculectomy group than in the DS group (24.6 versus 3.1%).<sup>54</sup> Bleb fibrosis and encapsulation may occur after NPGS, and their incidence is comparable with that after trabeculectomy. The rate of post-operative 5-fluorouracil (5-FU) injection for uncontrolled IOP after DS (with or without implant and/or antimetabolites) ranges between 4.6 and 56%, and may be as high as 35% following VCS.<sup>33</sup>

### Efficacy of Non-penetrating Glaucoma Surgery

The last years have witnessed numerous publications on NPGS. If the safety margin of glaucoma surgery could be increased significantly without sacrificing efficacy, surgical intervention for glaucoma could be considered earlier.

### Deep Sclerectomy

Prospective studies of DSCI report complete success rates of 45–69%,<sup>30,55–58</sup> with qualified success rates (IOP <21mmHg with medication) being much higher. In addition, the use of a collagen implant enhances success rates and reduces the need for post-operative medications.<sup>20,30,58</sup> Shaarawy et al.<sup>58</sup> reported their long-term results of a randomised prospective trial of 104 eyes comparing DS with and without an implant. The complete success rate (IOP  $\leq$ 21mmHg without medication) was 34.6% at 48 months for the DS group and 63.4% for the DSCI group. The qualified success rate was 78.8% at 48 months and 94% for the DSCI group. The mean number of medications was reduced in the latter group and no significant operative complications were observed in either group. These results were confirmed by a subsequent study of 26 eyes reported by the same author, who randomly assigned a collagen implant to one eye of each patient with the contralateral eye of the same patient having DS without implant.<sup>30</sup> The complete success rate (IOP <21mmHg without medication) was 38% at 48 months for the DS-treated eyes and 69% for the DSCI-treated eyes, with the qualified success rate being 69 and 100%, respectively.

### Viscocanalostomy

The largest study of VCS, reported by Stegmann et al.<sup>8</sup> in 1999, was a prospective study of 214 eyes of 157 African patients with OAG with an average follow-up of 35 months. They reported a complete success rate (IOP  $\leq$ 22mmHg without medication) in 82.7% of eyes. The qualified success rate (IOP  $\leq$ 22mmHg with topical betaxolol hydrochloride) was achieved in 89% of eyes. Shaarawy et al.<sup>32</sup> presented their long-term results of VCS in a prospective trial in which 57 eyes of 57 Caucasian patients were consecutively enrolled. The complete success rate (IOP <21mmHg without medication) was 60%, whereas the qualified success rate (IOP <21mmHg

with or without medication) was 90% at 60 months. Both studies concluded that VCS provides reasonable long-term IOP control with few post-operative complications. Several other studies have been published, reporting results on the safety and efficacy of both DS and VCS. A recent meta-analysis based on 35 studies published between 2000 and 2005 reporting results of NPGS for OAG<sup>33</sup> found that the mean percentage of cases achieving  $\leq$ 21mmHg was 48.6% after primary DS, 68.7% after DS with implant, 67.1% after DS with antimetabolite, 51.1% after primary VSC and 36.8% after VSC with antimetabolite or implant. With lower IOP targets, the rates of success varied between 35 and 86% for DS and between 10 and 67% for VSC. The mean follow-up of the studies was in the three-year range.

### Comparative Studies Between Trabeculectomy and Non-penetrating Glaucoma Surgery

One of the most intriguing questions regarding NPGS is how well it fares compared with trabeculectomy, which was regarded for many decades as the gold standard against which all novel glaucoma procedures were tested. Randomised controlled trials comparing NPGS with trabeculectomy have a consensus on the superior safety profile of NPGS, but are not in agreement when it comes to efficacy, where we find conflicting results in terms of how low NPGS affects IOP compared with trabeculectomy. This is attributed to a number of factors, including the fundamental differences between NPGS and penetrating filtering techniques, the long learning curve of NPGS and the need to use goniotomy to achieve target IOPs. Yalvac et al.<sup>59</sup> and Carassa et al.<sup>60</sup> conducted comparative studies between VCS and trabeculectomy with a mean follow-up of three and two years, respectively. They both concluded that trabeculectomy provides lower IOPs, but is associated with higher complication rates. However, cumulative percentage probabilities of success were not statistically different between the two groups. We should also state that the authors either decided not to attempt goniotomy in those VCS eyes with post-operative IOP elevations, thus excluding a potential number of patients who could benefit from this adjunctive procedure, or considered it as a surgical failure.

El Sayyad et al.<sup>61</sup> prospectively compared the efficacy and safety of DS without implant with trabeculectomy in bilateral primary OAG. At 12-month follow-up there was no statistical significance between the two groups regarding both the complete and qualified success rates. However, there was a significantly lower incidence of complications for the DS group compared with the trabeculectomy group. Chiselita et al.<sup>62</sup> also considered DS without collagen implant against trabeculectomy in a randomised study, and showed the latter to be more effective at lowering IOP at 18 months, but with a higher complication rate. However, it should be noted that the authors did not perform goniotomy during the follow-up and their non-penetrating technique differed in that only the external wall of the Schlemm's canal was removed, without peeling its inner part and the adjacent trabecular meshwork. In our judgement, considering goniotomy to be a failure criterion could be comparable to considering suture lysis and capsulotomy as failure criteria of glaucoma and cataract surgeries, which is mostly uncommon.

Mermoud et al.<sup>57</sup> prospectively compared two groups: DSCI (44 eyes) versus trabeculectomy (44 eyes). The complete success rates (IOP <21mmHg without medication) were 57% for the trabeculectomy group versus 69% for the DSCI group. The number of post-operative medications was significantly lower in the DSCI group. The authors concluded that

success rates of both DSCI and trabeculectomy were comparable; however, a lower rate of complications was observed in the DSCI group.

## Conclusions

NPGS continues to evolve as a technique. It is certainly safer than trabeculectomy and thus may have a worthwhile role earlier in the treatment process. Its superior safety profile makes it a first choice in many cases. The major controversy that arises is the success rates of NPGS compared with trabeculectomy, with trabeculectomy being perceived by

many to lower IOP to a greater degree. The learning curve of NPGS and the need to consider goniotomy as an adjuvant to the procedure and not as a failure criterion cannot be overstated. The use of implants in NPGS offers better IOP control for longer periods, thus enhancing success rates. Variable definitions of success, different follow-up times and variable study designs make direct comparisons between reported results challenging. A prospective, randomised multicentre study is needed to draw final conclusions on how NPGS fares compared with trabeculectomy and to examine the different techniques. ■

- Krasnov MM, Sinusotomy in Glaucoma, *Vestn Oftalmol*, 1964; 7737–41.
- Sugar HS, Experimental trabeculectomy in glaucoma, *Am J Ophthalmol*, 1961;51:623
- Cairns JE. Trabeculectomy. Preliminary report of a new method. *Am J Ophthalmol*, 1968;66(4):673–9.
- Zimmerman TJ, Kooner KS, Ford VJ, et al., Trabeculectomy vs. nonpenetrating trabeculectomy: a retrospective study of two procedures in phakic patients with glaucoma, *Ophthalmic Surg*, 1984;15(9):734–40.
- Arenas E, Trabeculectomy ab externo, *Highlights Ophthalmol*, 1991;1959–66
- Cherniavskii G, Mogilevskaya F, Suprun AV, et al., Effectiveness of sinusotomy in open angle glaucoma, *Vestn Oftalmol*, 1971; 520–23.
- Kozlov IM, Bagrov SN, Anisimova SY, et al., Nonpenetrating deep sclerectomy with collagen, *Eye Microsurgery*, 1990; 3157–62.
- Stegmann R, Pienaar A, Miller D, Visco canalostomy for open-angle glaucoma in black African patients, *J Cataract Refract Surg*, 1999;25(3):316–22.
- Smit BA, Johnstone MA, Effects of viscoelastic injection into Schlemm's canal in primate and human eyes: potential relevance to visco canalostomy, *Ophthalmology*, 2002;109(4): 786–92.
- Tamm ER, Carassa RG, Albert DM, et al., Visco canalostomy in rhesus monkeys, *Arch Ophthalmol*, 2004;122(12):1826–38.
- Klink T, Lieb W, Grehn F, Erbium-YAG laser-assisted preparation of deep sclerectomy, *Graefes Arch Clin Exp Ophthalmol*, 2000;238(9):792–6.
- Verges C, Llevat E, Bardavio J, Laser-assisted deep sclerectomy, *J Cataract Refract Surg*, 2002;28(5):758–65.
- Pallikaris IG, Kozobolis VP, Christodoulakis EV, Erbium:YAG laser deep sclerectomy: an alternative approach to glaucoma surgery, *Ophthalmic Surg Lasers Imaging*, 2003;34(5):375–80.
- Argento C, Sansaeu AC, Badoza D, Casiraghi J, Deep sclerectomy with a collagen implant using the excimer laser, *J Cataract Refract Surg*, 2001;27(4):504–6.
- Assia EI, Rotenstreich Y, Barequet IS, et al., Experimental studies on nonpenetrating filtration surgery using the CO<sub>2</sub> laser, *Graefes Arch Clin Exp Ophthalmol*, 2007;245(6):847–54.
- Maldonado-Bas A, Maldonado-Junyent A, Filtering glaucoma surgery using an excimer laser, *J Cataract Refract Surg*, 2001; 27(9):1402–9.
- Bahar I, Kaiserman I, Trope GE, Rootman D, Non-penetrating deep sclerectomy for glaucoma surgery using the femtosecond laser: a laboratory model, *Br J Ophthalmol*, 2007;91(12): 1713–14.
- Klink T, Schlunck G, Lieb W, et al., CO<sub>2</sub> excimer and erbium:YAG laser in deep sclerectomy, *Ophthalmologica*, 2008;222(2):74–80.
- Koslov VI, Bagrov SN, Anisimova M, et al., Deep sclerectomy with collagen, *Eye Microsurgery*, 1990;344–46.
- Sanchez E, Schnyder CC, Sickenberg M, et al., Deep sclerectomy: results with and without collagen implant, *Int Ophthalmol*, 1996;20(1–3):157–62.
- Chiou AG, Mermoud A, Underdahl JP, Schnyder CC, An ultrasound biomicroscopic study of eyes after deep sclerectomy with collagen implant, *Ophthalmology*, 1998;105(4):746–50.
- Sourdille P, Santiago PY, Ducournau Y, Non-perforating surgery of the trabeculum with reticulated hyaluronic acid implant: why, how, what results?, *J Fr Ophthalmol*, 1999;22(7):794–7.
- Dahan E, Ravinet E, Ben-Simon GJ, Mermoud A, Comparison of the efficacy and longevity of nonpenetrating glaucoma surgery with and without a new, nonabsorbable hydrophilic implant, *Ophthalmic Surg Lasers Imaging*, 2003;34(6):457–63.
- Contreras I, Noval S, Munoz-Negrete FJ, et al., Ultrasound biomicroscopy in deep sclerectomy with a new acrylic implant, *Arch Soc Esp Ophthalmol*, 2006;81(8):445–50.
- Mansouri K, Shaarawy T, Wedrich A, Mermoud A, Comparing polymethylmethacrylate implant with collagen implant in deep sclerectomy: a randomized controlled trial, *J Glaucoma*, 2006; 15(3):264–70.
- Weyill MT, Meyer D, Van Aswegen E, A pilot study of deep sclerectomy with implantation of chromic suture material as a collagen implant: medium-term results, *Eye*, 2005;19(5): 549–54.
- Mousa AS, Preliminary evaluation of nonpenetrating deep sclerectomy with autologous scleral implant in open-angle glaucoma, *Eye*, 2007;21(9):1234–8.
- Liu ZR, Wang J, Effect of non-penetrating trabecular surgery with amniotic membrane implant on patients with juvenile glaucoma, *Zhonghua Yan Ke Za Zhi*, 2004;40(2):78–81.
- Shaarawy T, Flammer J, Smits G, Mermoud A, Low first postoperative day intraocular pressure as a positive prognostic indicator in deep sclerectomy, *Br J Ophthalmol*, 2004;88(5): 658–61.
- Shaarawy T, Mermoud A, Deep sclerectomy in one eye vs deep sclerectomy with collagen implant in the contralateral eye of the same patient: long-term follow-up, *Eye*, 2005;19(3): 298–302.
- Hamel M, Shaarawy T, Mermoud A, Deep sclerectomy with collagen implant in patients with glaucoma and high myopia, *J Cataract Refract Surg*, 2001;27(9):1410–17.
- Shaarawy T, Nguyen C, Schnyder C, Mermoud A, Five year results of visco canalostomy, *Br J Ophthalmol*, 2003;87(4): 441–5.
- Hondur A, Onol M, Hasanreisoglu B, Nonpenetrating Glaucoma Surgery: Meta-analysis of Recent Results, *J Glaucoma*, 2008; 17(2):139–46.
- Johnson DH, Johnson M, How does nonpenetrating glaucoma surgery work? Aqueous outflow resistance and glaucoma surgery, *J Glaucoma*, 2001;10(1):55–67.
- Cheng JW, Ma XY, Wei RL, Efficacy of non-penetrating trabecular surgery for open angle glaucoma: a meta-analysis, *Chin Med J (Engl)*, 2004;117(7):1006–10.
- Drolsum L, Long-term follow-up after deep sclerectomy in patients with pseudoexfoliative glaucoma, *Acta Ophthalmol Scand*, 2006;84(4):502–6.
- Chiou AG, Mermoud A, Jewelewicz DA, Post-operative inflammation following deep sclerectomy with collagen implant versus standard trabeculectomy, *Graefes Arch Clin Exp Ophthalmol*, 1998;236(8):593–6.
- Miserocchi E, Carassa RG, Bettin P, Brancato R, Visco canalostomy in patients with glaucoma secondary to uveitis: preliminary report, *J Cataract Refract Surg*, 2004;30(3): 566–70.
- Souissi K, El Afrit MA, Trojet S, Kraiem A, Deep sclerectomy for the management of uveitic glaucoma, *J Fr Ophthalmol*, 2006; 29(3):265–8.
- Tixier J, Dureau P, Becquet F, Dufier JL, Deep sclerectomy in congenital glaucoma. Preliminary results, *J Fr Ophthalmol*, 1999;22(5):545–8.
- Stangos AN, Whatham AR, Sunaric-Megevand G, Primary visco canalostomy for juvenile open-angle glaucoma, *Am J Ophthalmol*, 2005;140(3):490–96.
- Noureddin BN, El-Haibi CP, Cheikha A, Bashshur ZF, Visco canalostomy versus trabeculectomy ab externo in primary congenital glaucoma: 1-year follow-up of a prospective controlled pilot study, *Br J Ophthalmol*, 2006;90(10):1281–5.
- Rebolleda G, Munoz-Negrete FJ, Nonpenetrating deep sclerectomy for Sturge-Weber syndrome, *Ophthalmology*, 2001; 108(12):2152–2153.
- Audren F, Abitbol O, Dureau P, et al., Non-penetrating deep sclerectomy for glaucoma associated with Sturge-Weber syndrome, *Acta Ophthalmol Scand*, 2006;84(5):656–60.
- Zimmerman TJ, Kooner KS, Ford VJ, et al., Effectiveness of nonpenetrating trabeculectomy in aphakic patients with glaucoma, *Ophthalmic Surg*, 1984;15(1):44–50.
- Ravinet E, Tritten JJ, Roy S, et al., Descemet membrane detachment after nonpenetrating filtering surgery, *J Glaucoma*, 2002;11(3):244–52.
- Roy S, Mermoud A, Complications of deep nonpenetrating sclerectomy, *J Fr Ophthalmol*, 2006;29(10):1180–97.
- Shaarawy T, Karlen M, Schnyder C, et al., Five-year results of deep sclerectomy with collagen implant, *J Cataract Refract Surg*, 2001;27(11):1770–78.
- Cheema RA, Choong YF, Algawi KD, Delayed suprachoroidal hemorrhage following visco canalostomy, *Ophthalmic Surg Lasers Imaging*, 2003;34(3):209–11.
- Ciulla TA, Beck AD, Topping TM, Baker AS, Blebitis, early endophthalmitis, and late endophthalmitis after glaucoma-filtering surgery, *Ophthalmology*, 1997;104(6):986–95.
- Tamcelik N, Ozdamar A, Kizilkaya M, et al., Fungal keratitis after nonpenetrating glaucoma surgery, *Cornea*, 2002;21(5): 532–4.
- Mendrinios E, Dreifuss S, Dosso A, et al., Bacterial keratitis after nonpenetrating glaucoma surgery, *J Cataract Refract Surg*, 2008;34(4):707–9.
- AIGS I, The Advanced Glaucoma Intervention Study: 8. Risk of cataract formation after trabeculectomy, *Arch Ophthalmol*, 2001;119(12):1771–9.
- Anand N, Arora S, Clowes M, Mitomycin C augmented glaucoma surgery: evolution of filtering bleb avascularity, transconjunctival oozing, and leaks, *Br J Ophthalmol*, 2006; 90(2):175–80.
- Karlen ME, Sanchez E, Schnyder CC, et al., Deep sclerectomy with collagen implant: medium term results, *Br J Ophthalmol*, 1999;83(1):6–11.
- Shaarawy T, Mansouri K, Schnyder C, et al., Long-term results of deep sclerectomy with collagen implant, *J Cataract Refract Surg*, 2004;30(6):1225–31.
- Mermoud A, Schnyder CC, Sickenberg M, et al., Comparison of deep sclerectomy with collagen implant and trabeculectomy in open-angle glaucoma, *J Cataract Refract Surg*, 1999;25(3): 323–31.
- Shaarawy T, Nguyen C, Schnyder C, Mermoud A, Comparative study between deep sclerectomy with and without collagen implant: long term follow up, *Br J Ophthalmol*, 2004;88(1): 95–8.
- Yalvac IS, Sahin M, Eksioglu U, et al., Primary visco canalostomy versus trabeculectomy for primary open-angle glaucoma: three-year prospective randomized clinical trial, *J Cataract Refract Surg*, 2004;30(10):2050–57.
- Carassa RG, Bettin P, Fiori M, Brancato R, Visco canalostomy versus trabeculectomy in white adults affected by open-angle glaucoma: a 2-year randomized, controlled trial, *Ophthalmology*, 2003;110(5):882–7.
- El Sayyad F, Helal M, El-Kholify H, et al., Nonpenetrating deep sclerectomy versus trabeculectomy in bilateral primary open-angle glaucoma, *Ophthalmology*, 2000;107(9):1671–4.
- Chiselita D, Non-penetrating deep sclerectomy versus trabeculectomy in primary open-angle glaucoma surgery, *Eye*, 2001;15(Pt 2):197–201.